

Endothelial keratoplasty

Alvin L. Young, MMedSc, FRCSI, Srinivas K. Rao, FRCS, Lulu L. Cheng, FHKAM, Philip T. H. Lam, FRCOphth

Department of Ophthalmology and Visual Sciences, The Chinese University of Hong Kong, Prince of Wales Hospital, Hong Kong, China.

Correspondence and reprint requests:

Alvin L. Young, Department of Ophthalmology and Visual Sciences, Prince of Wales Hospital, Shatin, Hong Kong, China. E-mail: youngla@ha.org.hk

Abstract

Penetrating keratoplasty has been the standard procedure for treating diseases of the cornea. Recent advances in corneal surgery have enabled component surgery of the cornea to be performed, replacing only the necessary tissue instead of the entire cornea. Major changes occurring in corneal transplantation are related in part to better equipment, and recent improvements of surgical technique and advances in instrumentation have contributed to improved visual quality with lamellar keratoplasty surgery, making the procedures more accessible and easier to perform. The past decade has seen rapid advances in the field of lamellar surgery, particularly posterior lamellar graft for endothelial dysfunction — endothelial keratoplasty. The shift in corneal transplantation to endothelial keratoplasty is the beginning of an exciting new era in corneal transplant surgery. The aim of this article is to review the evolution of endothelial keratoplasty, the nomenclature, and the current status of endothelial transplantation.

Key words: Cornea, Keratoplasty, penetrating, Corneal transplantation

Penetrating keratoplasty (PK) has long been the standard procedure for treating diseases of the cornea. Recent advances in corneal surgery have enabled component surgery of the cornea to be performed, replacing only the necessary tissue instead of the entire cornea. Corneal components can be transplanted as lamellar sections of donor cornea or as *ex vivo* expanded cell sheets, with or without biologic carriers. Transplantation of cultivated epithelial sheets expanded from limbal epithelium or oral mucosal epithelium, deep lamellar keratoplasty (LK), and deep lamellar endothelial keratoplasty are already in clinical application.

The idea of component transplantation is simple and intuitive. The inherent philosophy is to leave the recipient's unaffected

corneal layers undisturbed. The aim is to do the minimal amount of resection for the greatest amount of benefit. However, this straightforward concept has proved difficult to put into practice until recently, mainly due to disappointing visual results. The major changes occurring in corneal transplantation are related in part to better equipment. Recent improvements of surgical technique and advances in instrumentation, as in the case of microkeratome-assisted lamellar transplantation, have contributed to improved visual quality with LK surgery. These recent advances are making the procedures more accessible and easier to perform, hence a resurgence of surgeons' interest in LK.

The past decade has seen rapid advances in the field of lamellar surgery, particularly posterior lamellar graft for endothelial dysfunction — endothelial keratoplasty (EK). The shift in corneal transplantation to EK is the beginning of an exciting new era in corneal transplant surgery. The aim of this article is to review the evolution of EK, the nomenclature, and the current status of endothelial transplantation (**Table 1**).

Evolution of endothelial keratoplasty

The first successful human corneal transplant surgery was performed more than 100 years ago on 7 December 1905 by Eduard Zirm,¹ and the first successful LK for visual improvement was performed by Arthur von Hippel in the latter part of the 19th century.² Corneal transplantation has changed relatively little during the past 50 years, from the initial square grafts of Castroviejo³ to the current round grafts.

Although PK has been shown to yield healthy donor tissue with good endothelial function, this procedure has been plagued by the inherent problems of unpredictable surface topography, retained surface suture-related complications, and poor wound strength.^{4,5} The quest for a lamellar surgical technique for endothelial transplantation has taken 2 different pathways: the anterior approach (corneal flap technique) and the posterior approach (corneal lamellar dissection technique).

Table 1. Glossary of endothelial keratoplasty acronyms and history of its evolution

Acronym	Procedure	Date introduced
ELK	Endothelial lamellar keratoplasty	1998 ¹⁵
PLK	Posterior lamellar keratoplasty	
	- Large incision	1999 ¹⁶
DLEK	Deep lamellar endothelial keratoplasty	
	- Large incision	2001 ¹⁷
	- Small incision	2004 ²⁰
Descemetorrhexis	Descemetorrhexis	2004 ²⁴
DSEK	Descemet stripping endothelial keratoplasty	2005 ²⁵
DSAEK	Descemet stripping automated endothelial keratoplasty	2006 ²⁶
DMEK	Descemet membrane endothelial keratoplasty	2006 ²⁸

Large-incision endothelial keratoplasty

EK by the corneal flap technique was explored as early as the 1960s.^{6,7} An anterior flap was created, either manually or with a microkeratome, which was then retracted to permit the recipient posterior stroma to be trephined out. A posterior lamellar button from the donor was then positioned in the recipient bed, and the flap was laid back over the new tissue and sutured into place. This technique was revived decades later and was termed endothelial lamellar keratoplasty (ELK) by Jones and Cuthbertson,⁸ endokeratoplasty by Busin et al,⁹ and microkeratome-assisted posterior keratoplasty by Azar et al.¹⁰ Although this procedure had the advantages of a microkeratome-assisted smooth dissection and easy 'open sky' access for other intraocular procedures, it ultimately fell out of favor because of interface haze, irregular astigmatism, unpredictable corneal topography, and problems related to the sutures or flap.^{11,12}

The concept of a scleral-limbal approach to corneal lamellar dissection for EK was first described by Ko et al in a rabbit model.¹³ These surgeons made an incision in the sclera and tunneled deep into the cornea, where they were able to remove the endothelium without touching the corneal surface. The endothelium was then replaced with donor tissue.

The first successful EK procedure in a human was performed by Tillett in 1956, with the posterior donor tissue sutured to the recipient bed.¹⁴ EK in its modern form was pioneered by Melles et al from The Netherlands.^{15,16} These were the first surgeons to perform a scleral-limbal procedure termed posterior lamellar keratoplasty (PLK) in humans without the use of sutures to secure the donor tissue in place. This technique involved creating a corneal stromal lamellar pocket through a limbal or scleral incision. The posterior stromal disc, along with the diseased endothelium, was excised using a specially designed low-profile trephine. After the initial trephine cut, specially designed microscissors were used to complete the cut, and the disc of tissue was removed from

the eye. Healthy donated posterior stroma and endothelium were placed endothelial side down on a viscoelastic-covered specially designed Dutch Ophthalmic Research Center spoon-shaped glide (DORC International, Zuidland, The Netherlands) for insertion into the recipient eye through a 9-mm limbal/scleral incision. The donor disc was initially harvested from whole donor eye but, subsequently, similar procedures have also been performed on donor corneoscleral rims using an artificial anterior chamber (**Figure 1**). A large air bubble was injected into the anterior chamber intraoperatively to tamponade the donor 'disc' towards the recipient stroma (**Figure 2**). The donor disc adheres to the recipient stroma through the endothelial pump mechanism, hydrophilic attraction of wet tissues, and other physical attachment factors. This technique eliminates the need for corneal sutures, requiring only scleral sutures to close the scleral/limbal wound.

The preliminary clinical results of PLK showed promise with respect to postoperative astigmatism and endothelial cell viability. At 6 to 12 months follow-up, the average postoperative astigmatism was 1.45 D and the average postoperative endothelial cell density was 2520 cells/mm.¹⁶ The procedure was innovative and promising, but technically demanding, and required the apposition of 2 manually dissected surfaces, thereby increasing the potential for interface opacity and glare.

The main reason for the large scleral incision required for Melles' approach was the need to introduce the trephine into the dissected stromal pocket.^{15,16} Despite a low profile, a significant separation of the wound lips was required to achieve proper central positioning of the trephine over the posterior corneal stroma.

During the same period, on the other side of the Atlantic, Terry and Ousley^{17,18} applied Melles principles^{15,16} and modified the instrumentation and surgical technique. Terry and Ousley began laboratory work in 1999 and performed the first operations in the USA in 2000.^{17,18} These surgeons also introduced the artificial anterior chamber for preparation of the donor tissue, and established the advantages and safety of using Healon viscoelastic for the procedure. Terry and Ousley also renamed this procedure deep lamellar endothelial keratoplasty (DLEK).^{17,18}

Small-incision endothelial keratoplasty

In 2002, Melles et al modified the PLK procedure, reducing the incision size to 5 mm and advocated that the tissue be folded in half for insertion (**Figure 3**).¹⁹ A single case report demonstrated the concept for a folded graft to clear the cornea, but the resultant loss of endothelial cell density was greater than that in the large-incision series. In 2005, Terry and Ousley also described a technique of small-incision DLEK using a 5-mm scleral incision, whereby the excision of the posterior stromal disc was achieved using specially designed highly curved scissors (Cindy scissors; Storz, San Dimas, USA) obviating the need for an intrastromal trephine.²⁰ The smaller incision improved wound strength to prevent eyes from possible rupture from minimal accidental trauma.

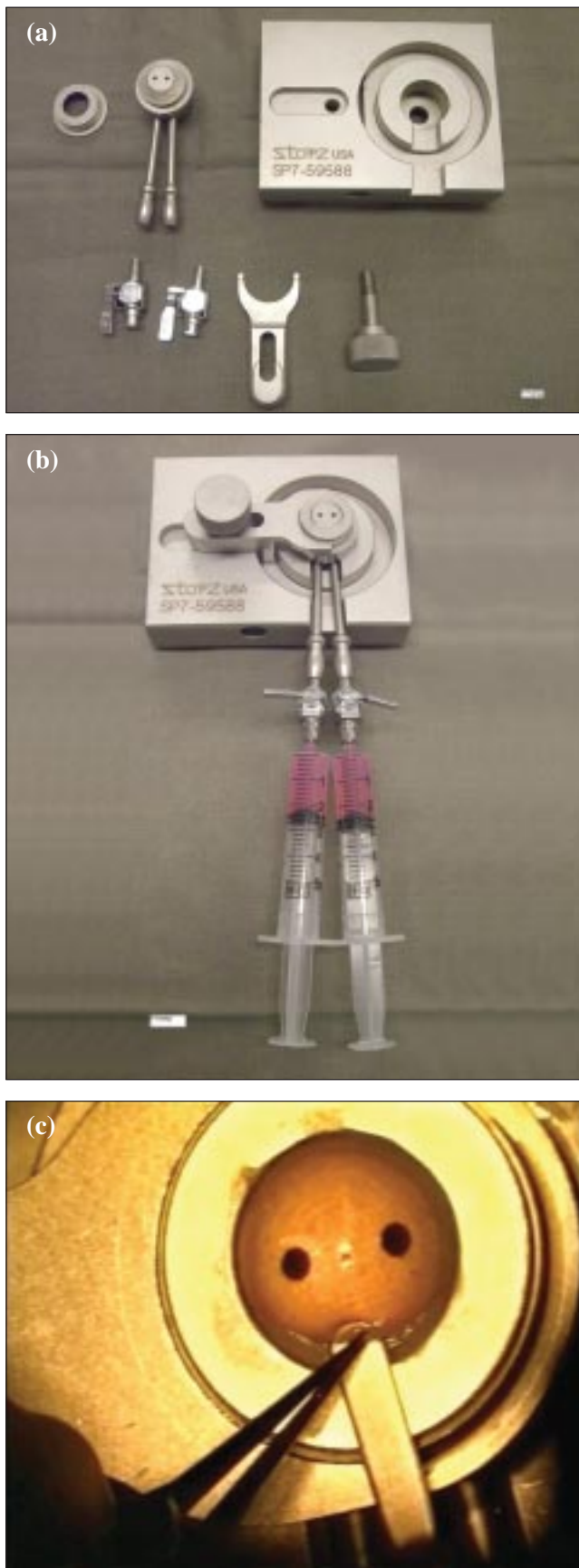

Figure 1. Example of an artificial chamber. (a) Unassembled chamber with its various components; (b) assembled chamber connected to 2 syringes containing Optisol; and (c) manual lamellar dissection of a posterior donor disc with the artificial chamber.

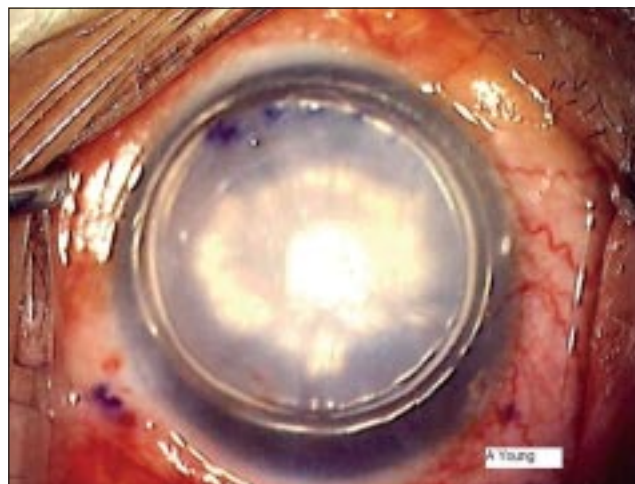


Figure 2. Intraoperative gas fill to tamponade against inserted donor disc in descemet stripping endothelial keratoplasty.

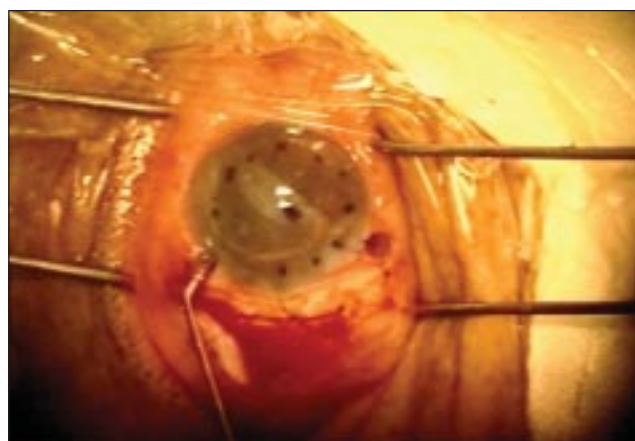


Figure 3. Folded donor disc after insertion in descemet stripping endothelial keratoplasty.

Short- and intermediate-term follow-up of these patients has shown encouraging results in terms of initial astigmatism, alteration in corneal contour, stability of the refraction, visual acuity, and endothelial cell count.^{21,22} These results for EK proved superior to the results obtained with standard full-thickness PK.

In an attempt to eliminate the need to perform recipient stromal dissection and to improve the smoothness of the recipient interface, a laboratory study was conducted to assess the feasibility of descemetorrhexis.²³ Melles et al later described descemetorrhexis, in which these researchers stripped only Descemet's membrane from the recipient and placed donor tissue directly onto the posterior surface (Figure 4).²⁴ This accomplished several objectives by producing a simpler procedure, which is less traumatic to the cornea and the anterior segment than PLK and DLEK, and by providing a potentially better optical interface, as the stroma lamellae are not dissected.

Around the same time, Price and Price were the first surgeons in the USA to publish clinical results of the descemetorrhexis technique, renaming it Descemet stripping endothelial

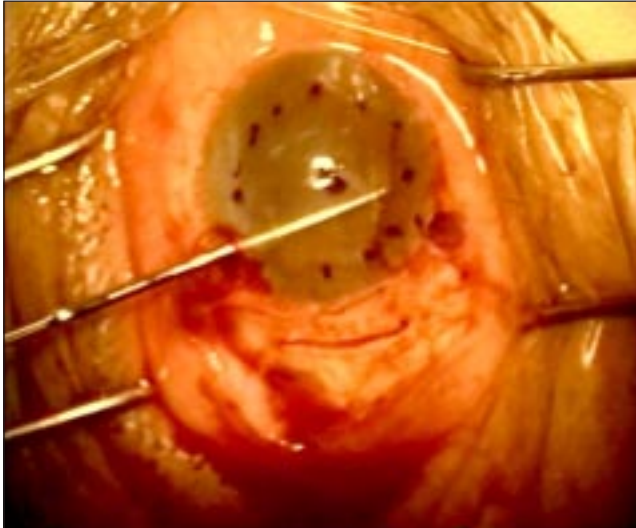


Figure 4. Descemet's membrane being stripped off the posterior stroma in descemet stripping endothelial keratoplasty.

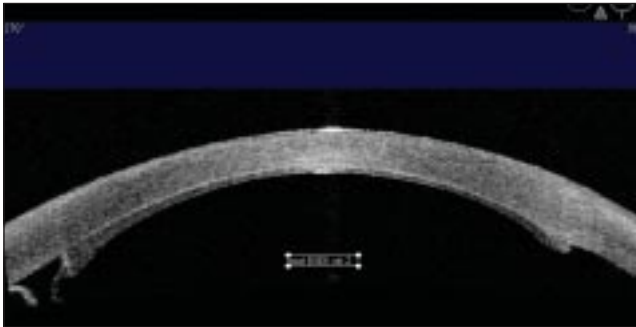


Figure 5. Optical coherence tomography 2 weeks after descemet stripping endothelial keratoplasty. The donor disc is well apposed, with a mismatch in the posterior bed tissue thickness.

keratoplasty (DSEK).²⁵ Other advantages of DSEK over DLEK include the obviation of complex recipient trephination techniques, reduced potential for trauma to the anterior chamber and lens, reduced possibility of inducing ectasia in patients with prior refractive surgery, and the ability to perform subsequent supplementary corneal refractive surgery should it be required later. However, current techniques do not allow the placement of a similar piece of donor tissue, hence the surgical technique is limited by the need to replace the recipient bed with a standard disc of posterior corneal stroma and endothelium from the donor eye. As a result, there is a mismatch between the thickness of the resected recipient tissue (**Figure 5**) and the donor tissue that replaces it. Preliminary experience with DSEK indicates a higher dislocation rate of the donor disc than with the standard DLEK technique. The higher dislocation rate is a result of the smoothness of the 2 opposing surfaces, the recipient DLEK surface being 'sticky' while that of DSEK is smooth. In addition, Price and Price noted many eyes treated with DSEK did not correct to 20/20 and the failure was ascribed to opacity at the graft-host interface.²⁵

DSEK further evolved into Descemet stripping automated endothelial keratoplasty (DSAEK) in which a motorized

microkeratome (eg, the Moria Automated Lamellar Therapeutic Keratoplasty microkeratome system [Moria, Antony, France]) is used to harvest the donor posterior lamella and endothelium.²⁶ With the recent introduction of an artificial anterior chamber and an automated motorized microkeratome, the need for manually dissecting the donor cornea leading to potential uneven depth is avoided. The automated microkeratome not only reduces the intraoperative time required to prepare the donor disc, but also provides a smoother interface. There are fewer perforations during automated dissection, and initial results of DSAEK showed better early postoperative visual acuity and fewer graft failures than earlier procedures.²⁷

Melles et al later described a new technique of pure Descemet membrane transplantation of 'DM rolls' through a 3.5-mm clear corneal tunnel small incision, 9.0 mm in diameter, termed Descemet membrane endothelial keratoplasty (DMEK).²⁸ Although theoretically promising, this procedure is difficult to complete because Descemet's membrane is fragile, lacks rigidity, and is difficult to position within the anterior chamber without stromal support.²⁹ The manipulation of donor tissue tolerated during the EK techniques may lead to wrinkles, spontaneous folds, tears, and unacceptable endothelial cell death when applied to DMEK (**Figure 6**). The first description of true endothelial cell (Tencell) transplantation in humans was reported by Tappin.³⁰ The initial series of DMEK reported by Melles et al demonstrated a 30% incidence of graft failure with this surgery, which was primarily attributed to difficulty with manipulations of this delicate tissue roll.³¹

Benefits and limitations of endothelial keratoplasty

The most suitable surgical candidates for EK would be patients with Fuch's disease or pseudophakic bullous keratopathy.³² EK may also be valuable for some patients with a failed PK, particularly those without significant stromal scarring, opacification, or vascularization of the anterior

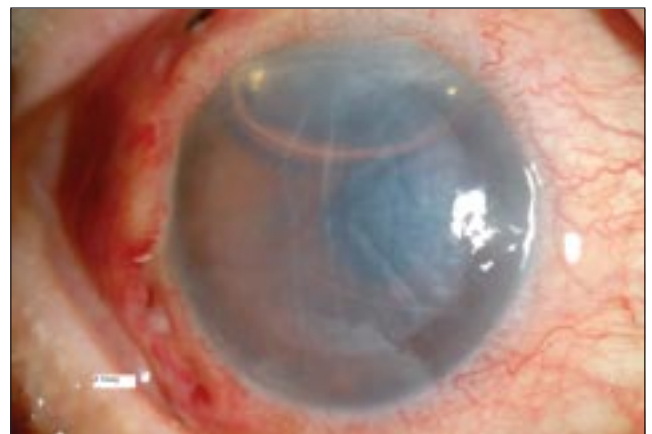


Figure 6. One day post-descemet stripping endothelial keratoplasty showing a securely attached donor disc, a residual gas bubble, and an edematous cornea with Descemet wrinkles on the donor disc.

layers. Pseudophakic patients with deep anterior chambers and posterior chamber intraocular lenses are the best candidates for the novice surgeon, as there is adequate space to unfold the donor button without risk of trauma to the lens. Similarly, for patients requiring both corneal transplantation and cataract removal, it is advantageous to perform a triple procedure with removal of the cataract just before the EK portion of the surgery. This allows the creation of a deeper anterior chamber and avoids the risk of damaging the donor graft.

The main benefits of EK include a stronger wound (absence of a full thickness incision), more rapid healing (**Figure 7**) and little or no change in refraction. Since the anterior layers remain undisturbed, there is no need for the use of surface corneal sutures as for traditional PK. The corneal curvature also remains more stable over time and the large shifts in refraction that sometimes occur with corneal grafts do not occur. Late suture-related complications such as infection or vascularization are prevented and the absence of a full-thickness vertical interface in the cornea increases the safety of the procedure, both during and after the operation. The absence of penetrating corneal sutures and incisions

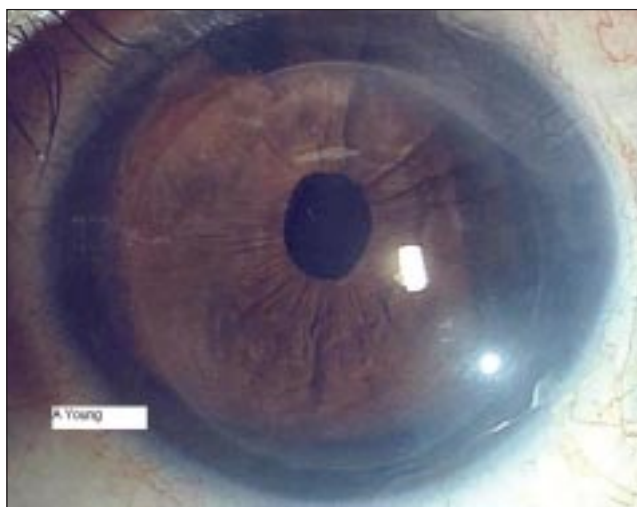

Figure 7. Three weeks post-descemet stripping endothelial keratoplasty.

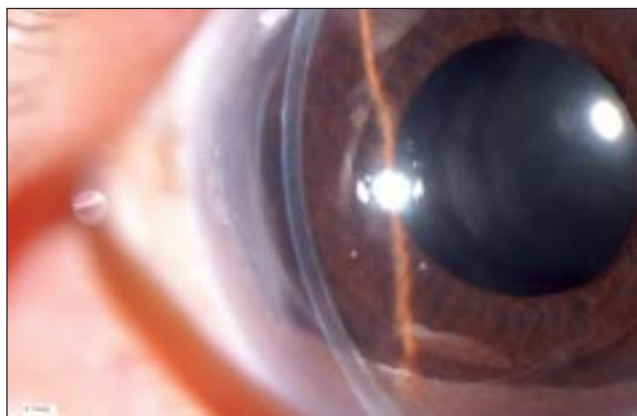


Figure 8. Clear cornea with a well-apposed thin graft post-descemet stripping endothelial keratoplasty.

results in reduced postoperative astigmatism, normal corneal topography, faster wound healing, earlier visual rehabilitation, and a more stable globe.^{19-21,32} In addition, rejection appears to be less frequent during the first 2 years after EK, and may be less severe after EK than after PK.³³ Should rejection occur, aggressive treatment may be considered, as for conventional PK.³⁴ The minimal alteration in the contour of the cornea after surgery means that the predictability of intraocular lens power calculations is enhanced. For DSEK, the entire recipient cornea is left intact, thus subsequent LASIK or other procedures may still be applied (**Figure 8**). In areas such as Hong Kong where grafts are scarce, the benefit of multiple recipients for 1 donated eye is also important.³⁵

On the other hand, there are limitations to EK. The main disadvantages include the need for specific instrumentation, a steeper learning curve, and the need for excellent surgical technique. EK requires a different skill set to that required for standard full thickness PK, so experienced PK surgeons may initially find the EK maneuvers awkward and unfamiliar. It is strongly recommended that EK should be extensively practiced in the laboratory before embarking on clinical treatment of patients. EK was first introduced to the Prince of Wales Hospital in Hong Kong by Terry in August 2005. Surgeons must be vigilant and meticulously attentive to each of the steps to minimize the possibility of significant EK-associated complications. However, at the Prince of Wales Hospital, the technique was found to be a feasible alternative for patients with endothelial failure and anatomically successful surgery was achievable. (Alvin Young et al; presented at the XXV European Society of Cataract and Refractive Surgeons; Stockholm, Sweden; 8-12 September 2007)

For DSEK, the hardest part of the procedure is the preparation of the donor tissue with manual lamellar dissection. For DLEK, in addition to the above, recipient dissection is also

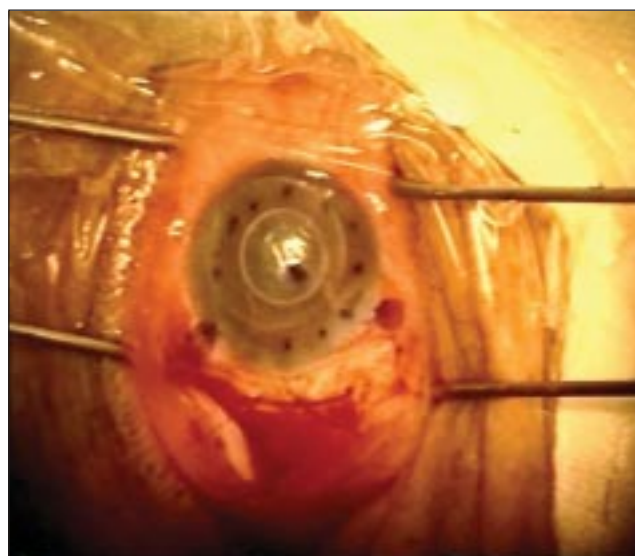


Figure 9. An unfolded donor disc with air in the anterior chamber.

required. In centers where a motorized microkeratome is available, DSAEK would obviate the need for manual dissection.²⁶ In addition, the introduction and access to femtosecond-assisted EK will further facilitate such procedures.³⁶

One inherent problem associated with small-incision EK is the unavoidable endothelial trauma associated with the folding and subsequent unfolding, the insertion of donor ‘taco’, and the use of intracameral air (**Figure 9**).¹⁹ The EK insertion forceps cause a reproducible pattern of endothelial damage, with 2 parallel bands and orthogonal wrinkles of devitalized nuclei noted in a parallel arrangement in an *in vitro* study.³⁷ At 6 months, the average central endothelial cell count after small incision DLEK/DSEK surgery (even after folding the tissue and other donor manipulation) was comparable to PK, and was not significantly different from large incision DLEK, for which the tissue was not folded.^{20,38} However, the mean donor cell loss after DSEK was as high as 34% and appeared to remain stable for up to 1 year.³⁹ Furthermore, longer term follow-up at 1 and 2 years after small-incision DLEK revealed significantly higher endothelial cell loss than after large-incision DLEK surgery.⁴⁰ The exact number of transplanted endothelial cells required to maintain graft clarity is variable, and is most likely related to the overall health of the transplanted donor endothelial cells.⁴¹

Price and Price⁴² and Terry et al⁴⁰ have both shown approximately 34% cell loss in Caucasian eyes. However, these are not equivalent to results in Asian Eyes. At the recent World Ophthalmology Congress 2008 in Hong Kong, 2 groups of researchers (from Singapore and Japan) showed approximately 60% cell loss after folding techniques in Asian eyes. In an attempt to minimize this inherent endothelial trauma, non-folding techniques devised for donor insertion include a pull-through technique involving the use of cartridge devices,⁴³ modified sheet glide,⁴⁴ or custom-made devices such as the Busin Glide Spatula (Moria). Mehta et al have devised a method for using the modified intraocular lens glide to pull the unfolded donor lenticule through the small incision with intraocular forceps to prevent significant endothelial trauma and surgical difficulties when the lenticule is unfolded.⁴⁴ These approaches may enable surgeons to pursue the goal of a small-incision technique without the expense of devastating endothelial cell loss, but follow-up of the central endothelial cell densities for more than 2 years will be necessary to establish the clinical safety of these various insertion approaches on long-term endothelial health.

Another postoperative complication is dislocation of the transplanted donor disc that can require surgical repositioning, especially in patients who rub their eyes. The smoother interface, especially for DSAEK compared with DLEK, was suggested to be related to a higher dislocation rate of 25%.²⁵ Grafts may be surgically repositioned, but endothelial cell counts at 6 months were found to be significantly lower than for grafts that had not undergone repositioning.²⁷ Using techniques to remove fluid from the donor-recipient graft interface, the donor detachment rate for DSEK may be reduced to 6%.⁴⁵ Terry et al have also

shown that peripheral recipient bed scraping can reduce the dislocation rate further to just 1%.⁴⁶

Common to all LK procedures, the presence of an interface may lead to an inherent potential for haze.⁴⁷ The presence of the interface can result in a marginal reduction (approximately 1 line of visual loss to the macular potential) in the quality of vision. This may be associated with interface irregularity arising from manual lamellar dissection. The interface may appear to be clear clinically, but it remains an interface with the donor tissue with a manual dissection.²²

Additional problems of EK are those common to PK, such as the risk of cataracts in patients with phakia and postoperative glaucoma. A recent study found that the falsely elevated intraocular pressure expected in patients with thick corneas was not demonstrated after DSEK. High intraocular pressure readings should thus be noted and managed accordingly.⁴⁸

Future directions

The 21st century heralds an era of tailored keratoplasty, treating only the diseased portion of the cornea and leaving the unaffected parts intact.⁴⁹ The recent advances that have taken place in the past decade and the technical and laboratory innovations that are on the horizon hold promise for a leap forward in surgeons’ ability to provide quick and excellent visual rehabilitation for patients with endothelial dysfunction. As one of the hardest parts of EK is the manual lamellar dissection of the donor disc, further development in eye banking and provision of endothelial discs using either an automated microkeratome or femtosecond laser will make the surgical technique easier and more reproducible.

The femtosecond laser is capable of precisely gauging and cutting the donor tissue to the desired depth, with minimal collateral tissue injury and without perforation. The laser can now be used to perform corneal pockets for ring segments, arcuate wedge-shaped resection for correction of high astigmatism, lamellar dissections for anterior lamellar keratoplasty, and donor tissue preparation for Descemet stripping endothelial keratoplasty and shaped full-thickness keratoplasty.^{50,51}

Centralized eye bank preparation of pre-cut donor tissue may be achieved by either microkeratome or femtosecond laser, resulting in viable grafts without significant endothelial cell loss at 2 days.^{52,53} The use of pre-cut tissue in a single-surgeon study of DSAEK yielded a low rate of early postoperative complications of graft dislocation and primary graft failure.⁵⁴ A larger scale prospective randomized study would be useful to evaluate postoperative vision and disc adherence.

Further refinements in surgical and biologic technology may take the limits of corneal regenerative medicine to new horizons. Intraoperative and postoperative topical wound

healing response modifiers, including steroids and biotech drugs, will become another area of innovation for the pharmaceutical industry to optimize surgical outcomes. The current work with in situ human corneal endothelial cell regeneration is exciting and complementary to the evolution of the surgical techniques of EK. Chen et al have demonstrated success in amplification of endothelium on a stromal carrier.⁵⁵ This technique has the potential for taking the recipient's peripheral endothelial cells, increasing the cell density in the laboratory, and then re-transplanting them back into the recipient's central cornea by EK. Mimura et al have successfully treated bullous keratopathy of the rabbit cornea with the injection of human endothelial cell precursor cells into the anterior chamber and subsequent eye-down positioning.⁵⁶ In the future, EK may no longer be necessary and

a simple injection of precursor endothelial cells into the anterior chamber may be all that is required.

These are exciting times for corneal surgeons. However, the value of any modification to various techniques must be subjected to scientific study to assess patient safety and visual outcome. The apparent advantages for the relative ease of surgery of any modification must not lead to a higher dislocation rate, primary graft failure rate, or other complication for EK.

Acknowledgments

I wish to acknowledge Ms Sharon K. W. Yuen for her secretarial assistance and Dr Amy Wong for assistance with the optical coherence tomography photograph (Figure 5).

References

- Zirm E. Eine erfolgreiche totale Keratoplastik. *Arch Ophthalmologie*. 1906;64:580-93.
- Von Hippel A. Über Transplantationen der Kornea. *Ber Ophthalmol Ges Heidelberg* 1886;18:54.
- Castroviejo R. Keratoplasty for the treatment of keratoconus. *Trans Am Ophthalmic Soc*. 1948;46:127-53.
- Abou-Jaoude ES, Brooks M, Katz DG, Van Meter WS. Spontaneous wound dehiscence after removal of single continuous penetrating keratoplasty suture. *Ophthalmology*. 2002;109:1291-6.
- Confino J, Brown SI. Bacterial endophthalmitis associated with exposed monofilament sutures following corneal transplantation. *Am J Ophthalmol*. 1985;99:111-13.
- Culbertson WW. Endothelial replacement: flap approach. *Ophthalmol Clin North Am*. 2003;16:113-118.
- Polack FM. Queratoplastia lamelar posterior. *Revista Peruana Oftalmologia*. 1965;2:62-4.
- Jones DT, Culbertson WW. Endothelial lamellar keratoplasty (ELK) [abstract]. *Invest Ophthalmol Vis Sci*. 1998;39(Suppl):S76. Abstract number: 342.
- Busin M, Arffa RC, Sebastiani A. Endokeratoplasty as an alternative to penetrating keratoplasty for the surgical treatment of diseased endothelium: initial results. *Ophthalmology* 2000;107:2077-82.
- Azar DT, Jain S, Sambursky R, Strauss L. Microkeratome-assisted posterior keratoplasty. *J Cataract Refract Surg*. 2001;27:353-6.
- Ehlers N, Ehlers H, Hjortdal J, Moller-Pedersen T. Grafting of the posterior cornea: description of a new technique with 12-month clinical results. *Acta Ophthalmol Scand*. 2000;78:543-6.
- Sandeep J, Azar DT. New lamellar keratoplasty techniques: posterior keratoplasty and deep lamellar keratoplasty. *Curr Opin Ophthalmol*. 2001;12:262-8.
- Ko W, Freuh B, Shield C, Costello M, Feldman S. Experimental posterior lamellar transplantation at the rabbit cornea [abstract]. *Invest Ophthalmol Vis Sci* 1993;34:1102.
- Tillett CW. Posterior lamellar keratoplasty. *Am J Ophthalmol*. 1956;41:530-3.
- Melles GR, Eggink FA, Lander F, et al. A surgical technique for posterior lamellar keratoplasty. *Cornea*. 1998;17:618-26.
- Melles GR, Lander F, Beekhuis WH, Remeijer L, Binder PS. Posterior lamellar keratoplasty for a case of pseudophakic bullous keratopathy. *Am J Ophthalmol*. 1999;127:340-1.
- Terry MA, Ousley PJ. Deep lamellar endothelial keratoplasty in the first United States patients: early clinical results. *Cornea*. 2001;20:239-43.
- Terry MA, Ousley PJ. Replacing the endothelium without corneal surface incisions or sutures: the first United States clinical series using the deep lamellar endothelial keratoplasty procedure. *Ophthalmology*. 2003;110:755-64.
- Melles GR, Lander F, Nieuwendaal C. Sutureless, posterior lamellar keratoplasty: a case report of a modified technique. *Cornea*. 2002 21:325-7.
- Terry MA, Ousley PJ. Small-incision deep lamellar endothelial keratoplasty (DLEK): six-month results in the first prospective clinical study. *Cornea*. 2005;24:59-65.
- Terry MA, Ousley PJ. In pursuit of emmetropia: spherical equivalent refraction results with deep lamellar endothelial keratoplasty (DLEK). *Cornea*. 2003;22:619-26.
- Terry MA, Ousley PJ. Rapid visual rehabilitation after endothelial transplants with deep lamellar endothelial keratoplasty (DLEK). *Cornea*. 2004;23:143-53.
- Melles GR, Lander F, Rietveld FJ. Transplantation of Descemet's membrane carrying viable endothelium through a small scleral incision. *Cornea*. 2002;21:415-8.
- Melles G, Wijdh RH, Nieuwendaal CP. A technique to excise the Descemet membrane from a recipient cornea (Descemetorhexis) *Cornea*. 2004;23:286-8.
- Price FW, Price MO. Descemet's stripping with endothelial keratoplasty in 50 eyes: a refractive neutral corneal transplant. *J Refract Surg*. 2005;21:339-45.
- Gorovoy MS. Descemet-stripping automated endothelial keratoplasty. *Cornea*. 2006;25:886-9.
- Terry MA, Ousley PJ. Deep lamellar endothelial keratoplasty (DLEK): early complications and their management. *Cornea*. 2006;25:37-43.
- Melles GR, Ong TS, Ververs B, van der Wees J. Descemet membrane endothelial keratoplasty (DMEK). *Cornea*. 2006;25:987-90.
- Shimmura S. Component surgery of the cornea. *Cornea*. 2004;23(8 Suppl):S31-5.
- Tappin M. A method for true endothelial cell (Tencell) transplantation using a custom-made cannula for the treatment of endothelial cell failure. *Eye*. 2007;21:775-9.
- Melles GR, Ong TS, Ververs B, Van der Wees J. Preliminary clinical results of Descemet membrane endothelial keratoplasty. *Am J Ophthalmol*. 2008;145:222-7.
- Kang PC, Klintworth GK, Kim T, et al. Trends in the indications for penetrating keratoplasty, 1980-2001. *Cornea*. 2005;24:801-803.
- Allan BD, Terry MA, Price FW Jr, Price MO, Griffin NB, Claesson M. Corneal transplant rejection rate and severity

- after endothelial keratoplasty. *Cornea*. 2007;26:1039-42.
34. Young AL, Rao SK, Cheng LL, Wong AK, Leung AT, Lam DS. Combined intravenous pulse methylprednisolone and oral cyclosporine A in the treatment of corneal graft rejection: 5-year experience. *Eye*. 2002;16:304-8.
 35. Vajpayee RB, Sharma N, Jhanji V, et al. One donor cornea for 3 recipients: a new concept for corneal transplantation surgery. *Arch Ophthalmol*. 2007;125:552-4.
 36. Cheng YY, Pels E, Nuijts RM. Femtosecond-laser-assisted Descemet's stripping endothelial keratoplasty. *J Cataract Refract Surg*. 2007;33:152-5.
 37. Ide T, Yoo SH, Goldman JM, Perez V, O'Brien TP. Descemet-stripping automated endothelial keratoplasty: effect of inserting forceps on DSAEK donor tissue viability by using an in vitro delivery model and vital dye assay. *Cornea*. 2007;26:1079-81.
 38. Terry MA, Ousley PJ. Deep lamellar endothelial keratoplasty (DLEK): visual acuity, astigmatism, and endothelial survival in a large prospective series. *Ophthalmology*. 2005;112:1541-9.
 39. Terry MA, Chen ES, Shamie N, Hoar KL, Friend DJ. Endothelial cell loss after Descemet's stripping endothelial keratoplasty in a large prospective series. *Ophthalmology*. 2008;115:488-96.
 40. Terry MA, Wall JM, Hoar KL, Ousley PJ. A prospective study of endothelial cell loss during the 2 years after deep lamellar endothelial keratoplasty. *Ophthalmology*. 2007;114:631-9.
 41. Rao SK, Leung AT, Young AL, Fan DS, Lam DS. Is there a minimum endothelial cell count for a clear cornea after penetrating keratoplasty? *Indian J Ophthalmol*. 2000;48:71-2.
 42. Price MO, Price FW Jr. Endothelial cell loss after descemet stripping with endothelial keratoplasty influencing factors and 2-year trend. *Ophthalmology*. 2008;115:857-65.
 43. Harvey TM. Small incision insertion of posterior lamellar button. *J Refract Surg*. 2006;22:429.
 44. Mehta JS, Por YM, Beuerman RW, Tan DT. Glide insertion technique for donor cornea lenticule during Descemet's stripping automated endothelial keratoplasty. *J Cataract Refract Surg*. 2007;33:1846-50.
 45. Price FW Jr, Price MO. Descemet's stripping with endothelial keratoplasty in 200 eyes: early challenges and techniques to enhance donor adherence. *J Cataract Refract Surg*. 2006;32:411-8.
 46. Terry MA, Shamie N, Chen ES, Hoar KL, Friend DJ. Endothelial keratoplasty: a simplified technique to minimize graft dislocation, iatrogenic graft failure and pupillary block. *Ophthalmology*. 2008;115:1179-86.
 47. Hindman HB, McCally RL, Myrowitz E, et al. Evaluation of deep lamellar endothelial keratoplasty surgery using scatterometry and wavefront analyses. *Ophthalmology*. 2007;114:2006-12.
 48. Vajaranant TS, Price MO, Price FW, Wilensky JT, Edward DP. Intraocular pressure measurements following descemet stripping endothelial keratoplasty. *Am J Ophthalmol*. 2008;145:780-6.
 49. Terry MA. The evolution of lamellar grafting techniques over 25 years. *Cornea*. 2000;19:611-6.
 50. Mian SI, Shtein RM. Femtosecond laser-assisted corneal surgery. *Curr Opin Ophthalmol*. 2007;18:295-9.
 51. Terry MA, Ousley PJ, Will B. A practical femtosecond laser procedure for DLEK endothelial transplantation: cadaver eye histology and topography. *Cornea*. 2005;24:453-9.
 52. Suwan-Apichon O, Reyes JM, Griffin NB, Barker J, Gore P, Chuck RS. Microkeratome versus femtosecond laser predissection of corneal grafts for anterior and posterior lamellar keratoplasty. *Cornea*. 2006;25:966-8.
 53. Jones YJ, Goins KM, Sutphin JE, Mullins R, Skeie JM. Comparison of the femtosecond laser (IntraLase) versus manual microkeratome (Moria ALTK) in dissection of the donor in endothelial keratoplasty: initial study in eye bank eyes. *Cornea*. 2008;27:88-93.
 54. Chen ES, Terry MA, Shamie N, Hoar KL, Friend DJ. Precut tissue in Descemet's stripping automated endothelial keratoplasty donor characteristics and early postoperative complications. *Ophthalmology*. 2008;115:497-502.
 55. Chen KH, Azar D, Joyce NC. Transplantation of adult human corneal endothelium ex vivo: a morphologic study. *Cornea*. 2001;20:731-7.
 56. Mimura T, Yokoo S, Araie M, Amano S, Yamagami S. Treatment of rabbit bullous keratopathy with precursors derived from cultured human corneal endothelium. *Invest Ophthalmol Vis Sci*. 2005;46:3637-44.