

# Surgical management of ectatic corneal disorders

Vishal Jhanji,<sup>1,2</sup> MD, Rasik B. Vajpayee,<sup>2</sup> MS, FRCS (Edin), FRANZCO

<sup>1</sup>Department of Ophthalmology and Visual Sciences, The Chinese University of Hong Kong, Hong Kong.

<sup>2</sup>Royal Victorian Eye and Ear Hospital, Centre for Eye Research Australia, University of Melbourne, Australia.

## Correspondence and reprint requests:

Dr. Vishal Jhanji, Department of Ophthalmology & Visual Sciences, The Chinese University of Hong Kong, 3/F Hong Kong Eye Hospital, 147K Argyle Street, Kowloon, Hong Kong. Email: vishaljhanji@cuhk.edu.hk

## Abstract

Ectatic disorders of the cornea such as keratoconus, pellucid marginal degeneration and post-refractive surgery corneal ectasia are characterized by progressive corneal thinning, irregular astigmatism and decreased visual acuity. Over the last decade, there has been a paradigm shift from penetrating keratoplasty to lamellar keratoplasty for the management of primary as well as acquired corneal ectasia. This article reviews some of the surgical approaches to the management of ectatic corneal diseases.

**Key words:** Corneal diseases; Keratoconus; Ophthalmologic surgical procedures

## Introduction

Ectatic disorders of the cornea are characterized by progressive corneal thinning, irregular astigmatism and decreased visual acuity.<sup>1</sup> They comprise primary conditions such as keratoconus, pellucid marginal degeneration (PMD) and iatrogenic corneal ectasia, all of which may occur after refractive procedures such as LASIK (laser in-situ keratomileusis) surgery.

Over the last decade there has been a paradigm shift from penetrating keratoplasty (PKP) to lamellar keratoplasty for the management of primary as well as acquired corneal ectasia. Several treatment modalities have emerged including collagen cross-linking, intrastromal implants, laser vision correction, and recent techniques in central and peripheral lamellar keratoplasty. This article reviews important surgical

approaches to the management of ectatic corneal diseases.

## Deep lamellar keratoplasty

PKP is the most commonly performed solid organ transplantation and has enjoyed a relatively high success rate compared to transplantation of other tissues. However, endothelial graft rejection is observed in approximately 20% of cases undergoing PKP.<sup>2</sup> Although the results of PKP in cases of keratoconus are very good, a variable number of keratoconus patients experience one or more endothelial rejection episodes, causing graft decompensation. Deep lamellar keratoplasty (DLK) is a surgical technique that can eliminate the risk of corneal endothelial graft rejection, and has comparable optical results to PKP. DLK has been successfully used to treat various corneal pathologies that spare the corneal endothelium.<sup>3,4</sup>

Not very long ago, the concept of a 'true' deep anterior lamellar keratoplasty (DALK) extending down to Descemet's membrane (DM) was proposed. Older literature does not expand on the actual depth of 'deep' lamellar keratoplasty. Gasset<sup>5</sup> reported a series of keratoconus patients in the late 1970s who underwent 'conectomy' and received full-thickness grafts stripped of DM, transplanted into relatively deep lamellar beds. Dissection of host tissue 'close to' the DM and the term DLK were first introduced by Archila in 1984,<sup>6</sup> with the use of intrastromal air injection to facilitate removal of diseased host corneal tissue. The first study on the results of DLK compared with PKP in keratoconus was reported by Sugita and Kondo in 1997.<sup>7</sup> They showed that postoperative visual acuity was similar after DLK and PKP in cases of keratoconus. Recently DALK has gained popularity due to improvements in surgical techniques, and the availability of new surgical instruments and viscoelastics that have helped to improve surgical success and reduce surgery time.

**Table 1. Results of big-bubble deep anterior lamellar keratoplasty.**

Authors	Year	No. of eyes	Indication	BCVA $\geq$ 20/40	Perforation rate	Rejection
Anwar and Teichmann <sup>14</sup>	2002	181	Keratoconus	Not reported	9%	None reported
Al-Torbak et al <sup>15</sup>	2006	127	Keratoconus	75%	13%	3%
Fogla and Padmanabhan <sup>16</sup>	2006	13	Keratoconus	100%	15%	None
Bahar et al <sup>17</sup>	2008	17	Keratoconus	100%	7.6%	7.6%
Fontana et al <sup>18</sup>	2007	81	Keratoconus	100%	13%	2%
Feizi et al <sup>19</sup>	2010	129	Keratoconus	78%	4%	14.3%

Abbreviation: BCVA = best-corrected visual acuity.

## Techniques of deep lamellar keratoplasty

The classical technique for DLK involves the removal of host tissue layer by layer until the deep stroma or the DM is bared. While stromal fibers are difficult to visualize when the amount of tissue becomes minimal, injection of irrigation fluid causes swelling of stromal fibers that can then be manipulated. The 2 techniques of DLK that have become popular in recent times are the Melles and big-bubble techniques.

### Melles technique

Melles<sup>8</sup> technique involves injection of air into the anterior chamber that creates a mirror reflex to guide surgical instruments directly into the space between DM and the posterior stroma. The difference in refractive index between air and corneal tissue creates a reflex of the surgical knife, and the distance between the instrument and reflex can be used to judge the amount of stromal tissue. The blunt end of a microsurgery knife is used to dissect the stroma down to the DM, using the reflection of the knife observed at the air-to-endothelium interface as a guide. After creation of a small DM detachment with balanced salt solution, viscodissection is performed to further extend DM detachment. After complete dissection of the DM, the overlying stroma is removed to expose the smooth surface of DM.

### Modifications in Melles technique

Shimmura et al<sup>9</sup> modified the Melles technique by performing anterior lamellar keratectomy prior to air injection. Senoo et al<sup>10</sup> have used a sclerolimbic approach for performing DLK. The method uses trabeculectomy to detach the DM. A flap is made, as in trabeculectomy, and the region directly above the DM is reached under direct vision. DM is detached by hydrodelamination and viscoelastic material is used to maintain the supra DM space. Parmar et al<sup>11</sup> used a 5-mm-long scleral incision for corneal dissection close to the level of the DM. Using this technique, a scleral pocket incision is created with a crescent knife and dissection is carried into the clear cornea. Viscoelastic is injected into the scleral pocket to facilitate separation of DM from the corneal stroma.

Funnell et al<sup>12</sup> compared the outcomes and complications of DLK using Melles technique and PKP for keratoconus. There was no significant difference in the proportion of patients achieving 6/9 or better in the PKP and DLK groups.

The study found that DLK causes less astigmatism and also has the advantage of avoiding endothelial graft rejection. In another study, Watson et al<sup>13</sup> compared the DLK and PKP using Melles technique in patients with keratoconus. They found that best-corrected visual acuity (BCVA), refractive results and complication rates were similar in both groups.

### Big-bubble technique

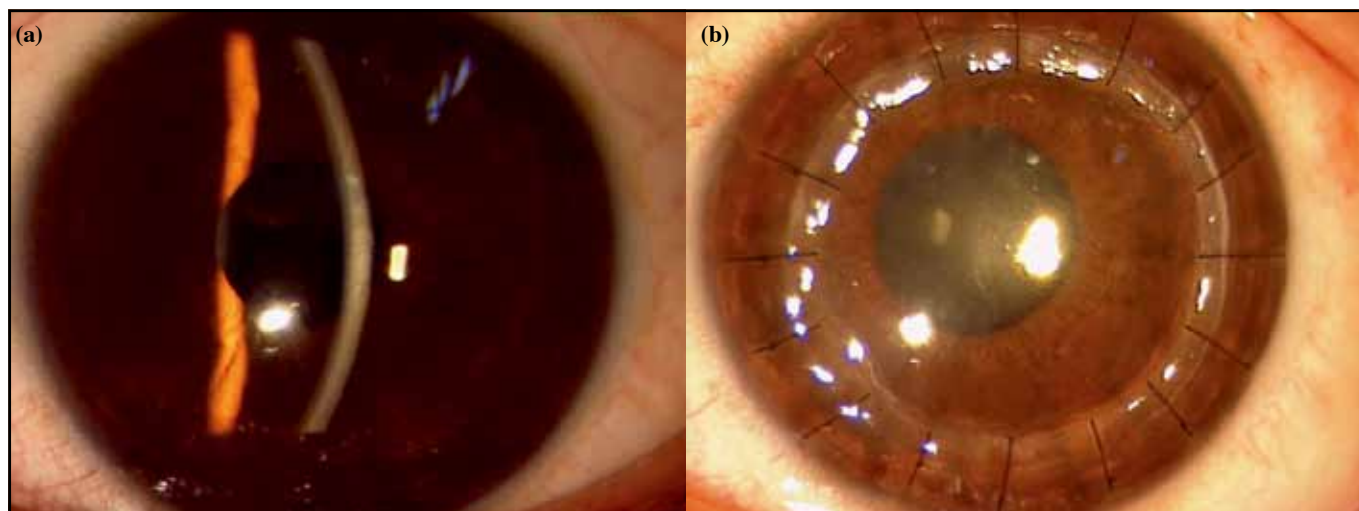
Archila<sup>6</sup> introduced the technique of air injection between the DM and the overlying corneal stroma. In this technique, a 26-gauge needle connected to a tuberculin syringe filled with air is inserted obliquely into the stroma up to the corneal midperiphery. Air is injected and corneal stromal trephination is done. Dissection of corneal stroma is facilitated with a spatula to separate the DM from the deeper stromal layers.

Anwar and Teichmann<sup>14</sup> modified Archila's technique by performing corneal trephination before air injection. About 60 to 80% of the corneal stroma is trephined with the help of a suction trephine. A 27-gauge needle attached to an air-filled syringe is bent at about 60° angulation 5 mm from its tip. The plunger of the air-filled syringe is depressed in order to form the big bubble between the DM and the deepest stroma. A partial thickness keratectomy is done with the help of a Beaver blade leaving a layer of corneal stroma in place. Using a sharp-tipped blade held tangentially to the cornea, a small nick is made in the corneal stroma. Dissection can be carried out in this plane with the help of a spatula and long scissors.

Since DLK does not involve replacement of the DM or endothelium, the donor quality criteria are not stringent. DM and endothelium are stripped off from the donor button which is then sutured over the host bed using 10-0 monofilament nylon sutures. The disparity between the host cut and donor button is usually between 0.25 mm and 0.5 mm, with the diameter of the graft button being larger.<sup>15</sup> Some corneal surgeons prefer using the same size or an undersized donor button in patients with keratoconus (**Figure 1**).<sup>4</sup> Several studies have reported good results with the DALK technique (**Table 1**<sup>14-19</sup>).

### Modifications in the technique of deep lamellar keratoplasty by air injection

Fournié et al<sup>20</sup> have described a modification of Anwar's big-bubble technique. The initial air injection is made in the



**Figure 1.** Slit lamp photograph showing (a) preoperative and (b) postoperative keratoconus after big-bubble deep anterior lamellar keratoplasty.

superficial corneal stroma. The aim of the first air injection is to induce corneal emphysema and facilitate superficial lamellar keratectomy. Subsequent dissection is carried out with the help of viscoelastic. Recently, Parthasarathy et al<sup>21</sup> reported a method of using a small air bubble in the anterior chamber to help determine if a successful big bubble was achieved. The small bubble helps the surgeon assess the extent of the big bubble in cases where the cornea is opaque or when air diffusion into the peripheral cornea prevents direct visualization into the anterior chamber.

The major complication encountered during DLK is intraoperative perforation of the DM. The frequency of DM perforation during DALK depends on the surgical technique and the expertise of the surgeon and varies.<sup>15,22,23</sup> Keratoconus patients are more prone to DM rupture than those with other diseases, either due to thinner corneas or an intrinsic property of the disease.<sup>24</sup>

DM perforation can be micro or a macro in form. Micro-perforations in the peripheral cornea can be managed by careful stromal dissection and air injection at the end of the surgery. If a microperforation occurs in the central cornea, there is a risk of double anterior chamber formation in the postoperative period. Injection into the anterior chamber of a mixture of sulfur hexafluoride with air, or perfluoropropane with air can also be used to temporarily seal microperforations, or to flatten any secondary anterior chamber formed after perforation.<sup>25</sup>

Conversion to a PKP may be required in some cases. In such a scenario, a complete dissection of the host cornea should be carried out. Use of 0.01% trypan blue dye may delineate any retained pieces of DM and facilitate dissection of the trephined host cornea.<sup>26</sup>

A rather rare complication after DLK is corneal stromal graft rejection. This is characterized by sudden onset of decreased vision, and subepithelial infiltrates, with or without stromal edema or anterior segment activity.<sup>27</sup> Such eyes are treated

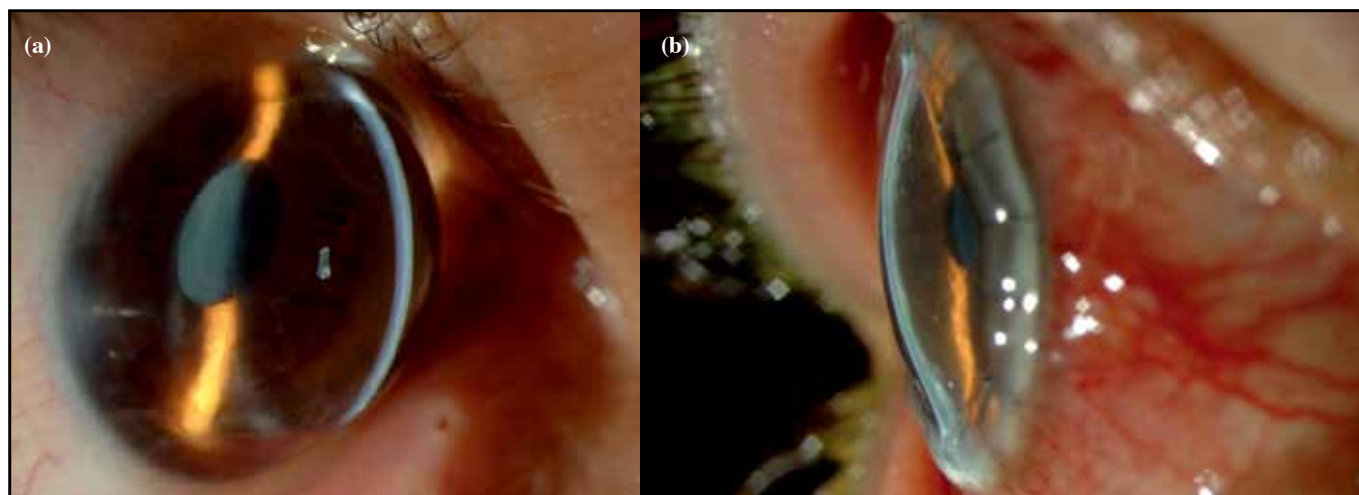
with 1% prednisolone acetate drops, gradually tapered over 4 to 6 weeks.

### Automated lamellar therapeutic keratectomy

Microkeratome-assisted lamellar keratoplasty is another novel technique used for surgically treating keratoconus and other corneal pathologies sparing the endothelium.<sup>28,29</sup> The major advantage of automated lamellar therapeutic keratectomy (ALTK) is that the donor cut is smooth which eliminates the risk of interface haze that can otherwise result in poor visual quality. Moreover, the dissection is easy to perform, and shortens surgical time considerably. The surgical technique offers more control in the depth of dissections and can be fairly standardized. The surgery does not require dissection up to the level of DM, therefore reducing the chances of perforation of DM.

ALTK has been primarily developed to treat cases of keratoconic corneas with a minimum corneal thickness of 380 microns.<sup>29</sup> A 250 microns anterior corneal disc of host is excised by a microkeratome and a 350 microns thick donor corneal disc is transplanted. The donor lenticule is also harvested using a microkeratome and an artificial anterior chamber. The desired diameter of the donor lenticule is achieved by using different suction rings.

Busin et al<sup>29</sup> evaluated the visual and refractive results of ALTK in patients with keratoconus with minimal corneal thickness of 380 microns. All patients underwent a standard ALTK surgical procedure. At the end of 1 year, best-spectacle-corrected visual acuity  $\geq 20/40$  and refractive astigmatism  $\leq 4$  diopters were achieved in majority of patients. The major complications reported in this study included irregular astigmatism (22%), high-degree astigmatism requiring secondary intervention (12%), epithelial interface ingrowth (2%) and cataract formation (2%).



**Figure 2.** (a) Preoperative and (b) postoperative photographs after ‘tuck in’ lamellar keratoplasty in a case with extreme corneal ectasia after keratoplasty.

### ‘Tuck in’ lamellar keratoplasty

‘Tuck in’ lamellar keratoplasty is a special technique of partial-thickness corneal transplantation that has been described for cases of advanced peripheral corneal thinning disorders like keratoglobus, PMD or cases with a combination of keratoconus and PMD.<sup>30,31</sup>

#### Surgical technique

The surgery involves the creation of partial-thickness groove of 180 to 240  $\mu\text{m}$  on the host cornea using a Hessburg Barron vacuum trephine and excision of a central anterior stromal disc. Subsequently, a peripheral intrastromal pocket is created circumferentially in the corneal periphery up to a point 0.5 mm farther away from the limbus. The donor preparation involves fixing a corneoscleral donor button in an artificial chamber. An initial partial thickness incision is made up to a depth of 300  $\mu\text{m}$  and superficial corneal tissue is excised leaving a central full-thickness graft with a peripheral partial-thickness flange of about 2.5 to 3 mm. The tissue is punched from the endothelial side with hand-held trephines. The DM of the donor lenticule is stripped after staining with 0.1 ml of 0.06% trypan blue. The flange of the donor lenticule is tucked into the peripheral intrastromal pocket of the host previously created, and sutured with sixteen 10-0 monofilament sutures. In the presence of inferior thinning in cases of PMD with keratoconus only, an inferior 180° peripheral intrastromal pocket is created instead of a circumferential pocket.

The central full-thickness graft provides tectonic support to the central cornea, while the thin peripheral flange tucked into the intrastromal pocket integrates into the host and provides tectonic support to the peripheral cornea. Moreover, there is no damage to the recipient’s limbal stem cells as dissection of limbal region is avoided, and subsequently this promotes healing of the epithelium at the graft-host junction (Figure 2).

### Intacs

Intacs are polymethylmethacrylate segments which were designed to be surgically inserted into the deep corneal stroma to flatten the central cornea. An important advantage they offer is that the prolate shape of the cornea is preserved over the central optical zone, which is unlike laser and incisional procedures that play a role in the maintenance of contrast sensitivity and improved visual acuity outcomes. Intacs were initially approved by the US Food and Drug Administration in 1999 for correction of myopia from  $-1.00$  to  $-3.00$  D, with 1.00 D or less of astigmatism. However, with the advent of the excimer laser at about the same time, Intacs were not popular for refractive correction. Intacs have now been approved for use in patients with mild-to-moderate keratoconus who have a clear visual axis, upper limit of keratometry readings in the range of 55 to 57 D, and a minimum corneal thickness of 400 microns.

Intacs come in many different sizes and potentially there are many different combinations that can be used to achieve both flattening of the central cornea and reduce the astigmatism. In pure nipple cones it is best to use 2 symmetrical Intacs. If the patient is not severely myopic, lesser-size symmetrical Intacs can be used so as not to overcorrect and induce hyperopia.

The surgical procedure involves creation of corneal tunnels at about 70% of corneal depth, using 2 Sinsky hooks and a mechanical spreader. Intacs segments are implanted in the respective corneal tunnels, maintaining a space of approximately 2.0 mm between their ends. The incision site is sutured using a single 10/0 nylon stitch.<sup>32</sup> Recently femtosecond laser has been used to create channels. Besides being quick, femtosecond results in a high degree of certainty about the depth of ring placements.

This technique may be associated with the occurrence of small epithelial defects that are evident on first postoperative

day. Deposits surrounding the ring segments are occasionally seen and may increase over time, but are not associated with effects on visual acuity. Infection most commonly occurs as a result of a loose stitch or as a gaping wound gape due to migration of the Intacs to the site of the wound.<sup>33-35</sup>

Colin et al in 2001<sup>36</sup> published the first series of 10 patients with 1-year follow-up. Intacs inserts of 0.45-mm thickness were placed in the inferior cornea and 0.25-mm thickness were inserted superiorly. Postoperative 12-month uncorrected visual acuity (UCVA) was significantly better than the preoperative UCVA. In 2003, Boxer Wachler et al<sup>37</sup> reported the results on 74 eyes of patients with keratoconus using asymmetrical Intacs. The study concluded that asymmetric Intacs implantation can improve both uncorrected and best-spectacle-corrected visual acuity and can reduce irregular astigmatism. In 2005, Alió et al<sup>38</sup> performed a prospective study to evaluate the effect of implanting 1 versus 2 intracorneal rings in patients with keratoconus. A single Intac was placed inferiorly in cases

where the topographic pattern did not cross the 180-degree meridian, whereas 2 Intacs were placed in cases where it crossed the 180-degree meridian. At 1 year, the mean UCVA improved from 20/100 to 20/32 in the first group and from 20/400 to 20/63 in the second group.<sup>38</sup> In 2005, Rabinowitz et al<sup>39</sup> compared the results of femtosecond laser with that of the mechanical spreader for inserting Intacs in patients with keratoconus. Both groups showed significant reduction in average keratometry, spherical equivalent, BCVA, UCVA, surface regularity index (SRI), and surface asymmetry index. The laser group performed better in all parameters except change in SRI.

## Conclusion

Lamellar surgeries have become popular in the management of primary as well as acquired corneal ectasia over the recent years. A more thorough understanding of these techniques should optimize outcomes in patients treated for corneal ectasia.

## References

1. Tan DT, Por YM. Current treatment options for corneal ectasia. *Curr Opin Ophthalmol*. 2007;18:284-9.
2. Kirkness CM, Ficker LA, Steele AD, Rice NS. The success of penetrating keratoplasty for keratoconus. *Eye*. 1990;4:673-88.
3. Vajpayee RB, Tyagi J, Sharma N, Kumar N, Jhanji V, Titiyal JS. Deep anterior lamellar keratoplasty by big-bubble technique for treatment corneal stromal opacities. *Am J Ophthalmol*. 2007;143:954-7.
4. Noble BA, Agrawal A, Collins C, Saldana M, Brogden PR, Zuberbuhler B. Deep Anterior Lamellar Keratoplasty (DALK): visual outcome and complications for a heterogeneous group of corneal pathologies. *Cornea*. 2007;26:59-64.
5. Gasset AR. Lamellar keratoplasty in the treatment of keratoconus: conectomy. *Ophthalmic Surg*. 1979;10:26-33.
6. Archila EA. Deep lamellar keratoplasty dissection of host tissue with intrastromal air injection. *Cornea*. 1984-1985;3:217-8.
7. Sugita J, Kondo J. Deep lamellar keratoplasty with complete removal of pathological stroma for vision improvement. *Br J Ophthalmol*. 1997;81:184-8.
8. Melles GR, Lander F, Rietveld FJ, Remeijer L, Beekhuis WH, Binder PS. A new surgical technique for deep stromal, anterior lamellar keratoplasty. *Br J Ophthalmol*. 1999;83:327-33.
9. Shimmura S, Shimazaki J, Omoto M, Teruya A, Ishioka M, Tsubota K. Deep lamellar keratoplasty (DLKP) in keratoconus patients using viscoadaptive viscoelastics. *Cornea*. 2005;24:178-81.
10. Senoo T, Chiba K, Terada O, et al. Deep lamellar keratoplasty by deep parenchyma detachment from the corneal limbs. *Br J Ophthalmol*. 2005;89:1597-600.
11. Parmar P, Salman A, Kalavathy CM, Thomas PA, Jesudasan NC. Simplified technique for deep anterior lamellar keratoplasty. *Cornea*. 2007;26:707-8.
12. Funnell CL, Ball J, Noble BA. Comparative cohort study of the outcomes of deep lamellar keratoplasty and penetrating keratoplasty for keratoconus. *Eye*. 2006;20:527-32.
13. Watson SL, Ramsay A, Dart JK, Bunce C, Craig E. Comparison of deep lamellar keratoplasty and penetrating keratoplasty in patients with keratoconus. *Ophthalmology*. 2004;111:1676-82.
14. Anwar M, Teichmann KD. Big-bubble technique to bare Descemet's membrane in anterior lamellar keratoplasty. *J Cataract Refract Surg*. 2002;28:398-403.
15. Al-Torbak AA, Al-Motowa S, Al-Assiri A, et al. Deep anterior lamellar keratoplasty for keratoconus. *Cornea*. 2006;25:408-12.
16. Fogla R, Padmanabhan P. Results of deep lamellar keratoplasty using the big-bubble technique in patients with keratoconus. *Am J Ophthalmol*. 2006;141:254-9.
17. Bahar I, Kaiserman I, Srinivasan S, Ya-Ping J, Slomovic AR, Rootman DS. Comparison of three different techniques of corneal transplantation for keratoconus. *Am J Ophthalmol*. 2008;146:905-12.
18. Fontana L, Parente G, Tassinari G. Clinical outcomes after deep anterior lamellar keratoplasty using the big-bubble technique in patients with keratoconus. *Am J Ophthalmol*. 2007;143:117-24.
19. Feizi S, Javadi MA, Jamali H, Mirbabaee F. Deep anterior lamellar keratoplasty in patients with keratoconus: big-bubble technique. *Cornea*. 2010;29:177-82.
20. Fournié P, Malecaze F, Coulet J, Arné JL. Variant of the big bubble technique in deep anterior lamellar keratoplasty. *J Cataract Refract Surg*. 2007;33:371-5.
21. Parthasarathy A, Por YM, Tan DT. Use of a "small-bubble technique" to increase the success of Anwar's "big-bubble technique" for deep lamellar keratoplasty with complete baring of Descemet's membrane. *Br J Ophthalmol*. 2007;91:1369-73.
22. Michieletto P, Balestrazzi A, Balestrazzi A, Mazzotta C, Occhipinti I, Rossi T. Factors predicting unsuccessful big bubble deep lamellar anterior keratoplasty. *Ophthalmologica*. 2006;220:379-82.
23. Leccisotti A. Descemet's membrane perforation during deep anterior lamellar keratoplasty: prognosis. *J Cataract Refract Surg*. 2007;33:825-9.
24. Jhanji V, Sharma N, Vajpayee RB. Intraoperative perforation of Descemet's membrane during "big bubble" deep anterior lamellar keratoplasty. *Int Ophthalmol*. 2010;30:291-5.
25. Den S, Shimmura S, Tsubota K, Shimazaki J. Impact of

the descemet membrane perforation on surgical outcomes after deep lamellar keratoplasty. *Am J Ophthalmol.* 2007;143:750-4.

26. Sharma N, Jhanji V, Titiyal JS, Amiel H, Vajpayee RB. Use of trypan blue dye during conversion of deep anterior lamellar keratoplasty to penetrating keratoplasty. *J Cataract Refract Surg.* 2008;34:1242-5.
27. Watson SL, Tuft SJ, Dart JK. Patterns of rejection after deep lamellar keratoplasty. *Ophthalmology.* 2006;113:556-60.
28. Vajpayee RB, Vasudendra N, Titiyal JS, Tandon R, Sharma N, Sinha R. Automated lamellar therapeutic keratoplasty (ALTK) in the treatment of anterior to mid-stromal corneal pathologies. *Acta Ophthalmol Scand.* 2006;84:771-3.
29. Busin M, Zambianchi L, Arffa RC. Microkeratome-assisted lamellar keratoplasty for the surgical treatment of keratoconus. *Ophthalmology.* 2005;112:987-97.
30. Vajpayee RB, Bhartiya P, Sharma N. Central lamellar keratoplasty with peripheral intralamellar tuck: a new surgical technique for keratoglobus. *Cornea.* 2002;21:657-60.
31. Kaushal S, Jhanji V, Sharma N, Tandon R, Titiyal JS, Vajpayee RB. "Tuck In" Lamellar Keratoplasty (TILK) for corneal ectasias involving corneal periphery. *Br J Ophthalmol.* 2008;92:286-90.
32. Rabinowitz YS. INTACS for keratoconus. *Int Ophthalmol Clin.* 2006;46:91-103.
33. Chalasani R, Beltz J, Jhanji V, Vajpayee RB. Microbial keratitis following intracorneal ring segment implantation. *Br J Ophthalmol.* 2009 Jun 9 [Epub ahead of print].
34. McAlister JC, Ardjomand N, Ilari L, Mengher LS, Gartry DS. Keratitis after intracorneal ring segment insertion for keratoconus. *J Cataract Refract Surg.* 2006;32:676-8.
35. Bourcier T, Borderie V, Laroche L. Late bacterial keratitis after implantation of intrastromal corneal ring segments. *J Cataract Refract Surg.* 2003;29:407-9.
36. Colin J, Cochener B, Savary G, Malet F, Holmes-Higgin D. INTACS inserts for treating keratoconus: one-year results. *Ophthalmology.* 2001;108:1409-14.
37. Boxer Wachler BS, Christie JP, Chandra NS, Chou B, Korn T, Nepomuceno R. Intacs for keratoconus. *Ophthalmology.* 2003;110:1031-40.
38. Alió JL, Artola A, Hassanein A, Haroun H, Galal A. One or 2 Intacs segments for the correction of keratoconus. *J Cataract Refract Surg.* 2005;31:943-53.
39. Rabinowitz YS, Li X, Ignacio TS, Maguen E. INTACS inserts using the femtosecond laser compared to the mechanical spreader in the treatment of keratoconus. *J Refract Surg.* 2006;22:764-71.

**Gauder**  
Precision made in Germany

# Brilliant Peel

新一代染色剂 无毒 内界膜染色

硅油

重水

重硅油

染色剂

德国品质  
歌德耗材