

# Global survey of lacrimal surgeons on practice of nasolacrimal duct obstruction amid COVID-19 pandemic

Chun Wah Lam<sup>1</sup>, MBBS (Hons), MRCSEd, AFCOphthHK; Tessa Fayers<sup>2</sup>, FRCOphth; Hunter Kwok Lai Yuen<sup>1</sup>, FRCOphth, FRCSEd, FCOphthHK; Reynaldo Javate<sup>3</sup>, FICS; Jane Olver<sup>4</sup>, FRCS, FRCOphth

<sup>1</sup>Hong Kong Eye Hospital, Hong Kong

<sup>2</sup>Department of Ophthalmology, Imperial College Healthcare NHS Trust, London, UK

<sup>3</sup>Department of Ophthalmology, University of Santo Tomas Hospital, Manila, Philippines

<sup>4</sup>Clinica London, London, UK

Correspondence and reprint requests:

Dr Chun Wah Lam, Hong Kong Eye Hospital, 147K Argyle Street, Kowloon, Hong Kong. Email: matthewlam300@gmail.com

## Abstract

**Objective:** To survey lacrimal surgeons worldwide on their practice of nasolacrimal duct obstruction amid the coronavirus disease 2019 (COVID-19) pandemic.

**Methods:** A 24-question survey was designed to investigate lacrimal surgeons worldwide on their practice of nasolacrimal duct obstruction before the COVID-19 outbreak, during the first wave of COVID-19 pandemic (Spring 2020), and during the study period (12 March 2021 to 12 May 2021). The survey was uploaded to a website, and the link of the survey was sent to international oculoplastic societies for further distribution to their members.

**Results:** A total of 570 respondents from 68 countries or regions were included in the analysis. During the study period, the preferred surgical technique for nasolacrimal duct obstruction was external dacryocystorhinostomy (DCR) [69.9%], followed by endoscopic DCR (46.0%). 95.1% of respondents performed silicone intubation. When the risk of COVID-19 infection was high, respondents preferred external DCR to endoscopic DCR. Respondents used higher levels of personal protective equipment for lacrimal irrigation and surgery during

the study period than before the COVID-19 outbreak, in compliance with guidelines on aerosol-generating medical procedures.

**Conclusions:** Amid the COVID-19 pandemic, the preferred surgical treatment worldwide for nasolacrimal duct obstruction remains external DCR. The experience gained from the COVID-19 pandemic enables lacrimal surgeons to better prepare for future pandemics.

*Key words:* COVID-19; Lacrimal duct obstruction; Surveys and questionnaires

## Introduction

In March 2020, the World Health Organization declared the coronavirus disease 2019 (COVID-19) a pandemic. The viral load of severe acute respiratory syndrome coronavirus 2 (SARS-CoV-2) isolated from bodily fluids is particularly heavy in the respiratory tract (including the nasal passages).<sup>1-6</sup> As the lacrimal system is contiguous with the nasal mucosa, orbital and lacrimal surgeons are at risk of infection during lacrimal irrigation and dacryocystorhinostomy (DCR); the risk is increased during manipulation of nasal mucosa in nasal endoscopy.

At the start of the pandemic, most services involving lacrimal drainage were suspended, as were other aerosol-

generating medical procedures (AGMP).<sup>7-11</sup> Variant strains with high infectivity kept emerging even after widespread coverage of vaccination.<sup>12-20</sup> Lacrimal surgeons adjust their practice to limit viral spread while gradually resuming lacrimal services. This study aims to survey lacrimal surgeons worldwide on their practice of nasolacrimal duct obstruction before the COVID-19 outbreak, during the first wave of COVID-19 pandemic (Spring 2020), and during the study period (12 March 2021 to 12 May 2021).

## Methods

A 24-question survey was designed to investigate lacrimal surgeons worldwide on their practice of nasolacrimal duct obstruction before the COVID-19 outbreak, during the first wave of COVID-19 pandemic (Spring 2020), and during the study period (12 March 2021 to 12 May 2021). The survey was uploaded to the website <https://kwiksurveys.com>, and the link of the survey was sent to British Oculoplastic Surgery Society, European Society of Ophthalmic Plastic and Reconstructive Surgery, Australian & New Zealand Society of Ophthalmic Plastic Surgeons, Asia Pacific Society of Ophthalmic Plastic and Reconstructive Surgery, and American Society of Ophthalmic Plastic and Reconstructive Surgery for further distribution to their members through emails or notice board. The survey was also sent to lacrimal surgeon networks in the Middle East and South America through emails and WhatsApp groups known by the authors. Participants were invited to leave their emails for the results of the survey and follow-up.

## Results

A total of 684 responses were received during the study

period from 12 March 2021 to 12 May 2021. After excluding those who were not performing lacrimal surgery and those who had incomplete responses with no useful data, 570 respondents from 68 countries or regions were included in the analysis (Figure). There was no duplicate response.

### During the study period (from 12 March 2021 to 12 May 2021)

During the study period (which was largely pre-vaccination and before the emergence of Delta and Omicron variants), 65.9% of respondents considered their countries in an increasing phase of infection, whereas 34.1% of respondents reported low/decreasing/stable infection rates in their countries or regions (eg, Australia, New Zealand, and Taiwan).

97.4% of respondents reported resumption of part, if not all, of lacrimal services; only 2.6% of respondents were still not seeing patients needing lacrimal services. For lacrimal assessment, 86.4% of respondents resumed syringing and probing and 31.2% resumed nasal endoscopy for routine epiphora in those without COVID-19 symptoms, whereas 8.6% deferred these diagnostic tests in accordance with governmental orders or institutional guidelines or at individual discretion. For lacrimal surgery, 73.6% of respondents resumed all lacrimal surgery with no restrictions from their institutions, whereas 21.7% resumed urgent lacrimal surgery only and 4.7% were not permitted to perform lacrimal surgery.

For preoperative viral testing, 73.0% and 16.3% of respondents performed SARS-CoV-2 testing on all patients and high-risk patients, respectively, whereas 10.7% of respondents performed no testing, mainly because of

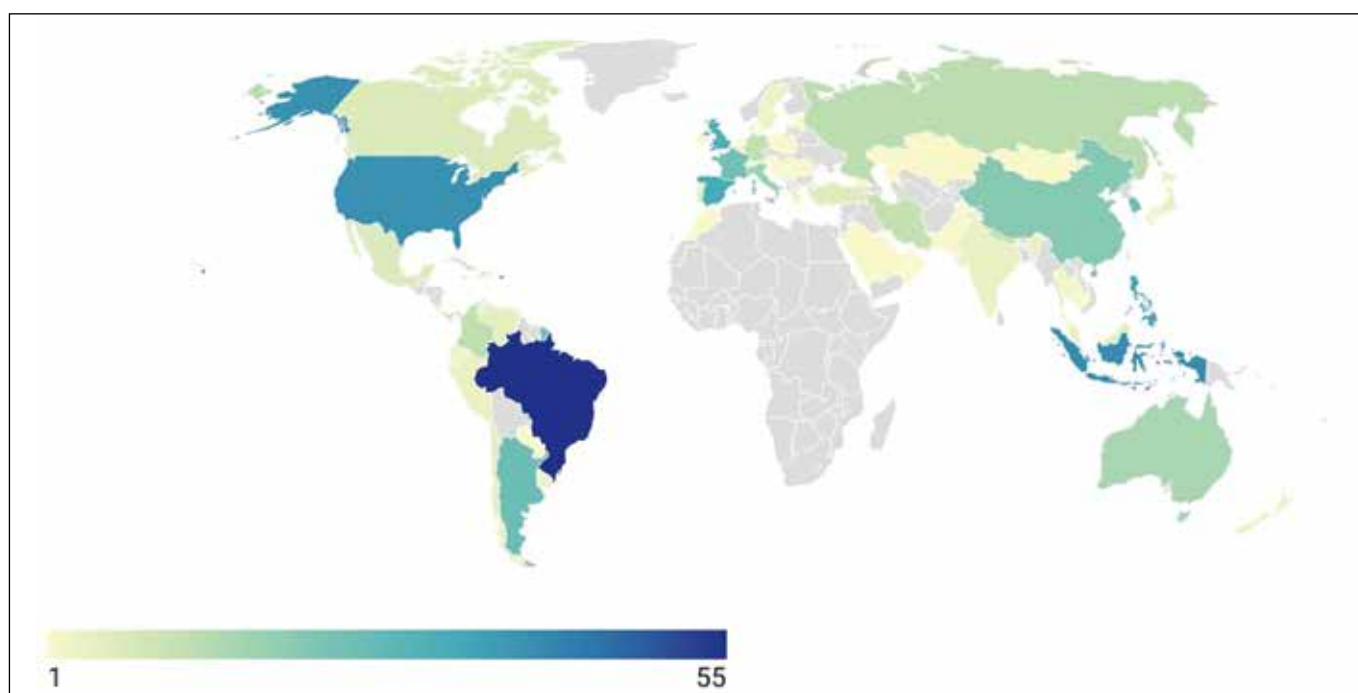


Figure. Worldwide distribution of respondents.

logistic or administrative reasons, or low infection rates in their regions. For those who performed testing, 81.3% of respondents used the nasal polymerase chain reaction test, 9.7% used the nasal rapid antigen test, 1.7% used the serum antibody test, and 3.9% used the saliva test.

For personal protective equipment (PPE), during syringing and probing, 4.7% of respondents reported not using any PPE, whereas 43.5% and 49.5% reported wearing a surgical mask and a N95 mask, respectively, with or without a face shield. During nasal endoscopy, 37.3% and 54.6% of respondents reported wearing a surgical mask and a N95 mask, respectively, with or without a face shield. During lacrimal surgery, 55.1% of respondents reported wearing a N95 mask and 24.3% reported wearing a face shield. Compared with before the COVID-19 outbreak, during the study period more respondents opted to wear a N95 mask (35.7% vs 49.5%,  $p<0.01$ ) or a face shield (15.4% vs 24.9%,  $p<0.01$ ) during syringing and probing, and more respondents opted to wear a N95 mask (40.6% vs 55.1%,  $p<0.01$ ) or a face shield (14.2% vs 24.3%,  $p<0.01$ ) during lacrimal surgery (Table 1).

For nasolacrimal duct obstruction, the preferred technique

was external DCR (69.9%), followed by endoscopic DCR (46.0%), lacrimal recanalization (21.3%), and balloon dacryoplasty (4.7%). 15.3% of respondents preferred both endoscopic and external DCR. These proportions were comparable with those before the COVID-19 outbreak ( $p=0.873$ ). Among respondents in countries with high COVID-19 infections, 62.6% preferred external DCR and 26.2% preferred endoscopic DCR, whereas among respondents in countries with low or stable COVID-19 infections, 39.5% preferred external DCR and 39.5% preferred endoscopic DCR ( $p<0.01$ ).

95.1% of respondents performed silicone intubation. Of them, 37.9% chose to remove the tube by direct visualization of the nose and retrieving the cut tubes with forceps, whereas 20.9% chose to retrieve the tube by endoscopic guidance. 95.3% of respondents removed the tube in outpatient consultation rooms or minor treatment rooms and 4.5% in the operating theater (Table 2).

### Before COVID-19 outbreak

The preferred lacrimal surgery procedure was external DCR (72.8%), followed by endoscopic endonasal DCR (46.0%), lacrimal recanalization (22.8%), and balloon

**Table 1. Choice of personal protective equipment during syringing and probing, lacrimal surgery, and nasal endoscopy before the COVID-19 outbreak and during the study period (12 March 2021 to 12 May 2021)\***

Personal protective equipment	Before the COVID-19 outbreak		During the study period (12 March 2021 to 12 May 2021)		
	Syringing and probing	Lacrimal surgery	Syringing and probing	Lacrimal surgery	Nasal endoscopy
No personal protective equipment	19.8	3.0	4.7	0.6	5.1
Surgical mask alone	37.9	49.1	37.1	32.7	31.9
N95 mask alone	25.4	30.4	31.8	36.6	33.2
Surgical mask and face shield	4.1	3.5	6.4	5.6	5.4
N95 mask and face shield	10.4	10.2	17.7	18.5	21.4
Face shield alone	0.9	0.5	0.9	0.2	1.0
Powered air-purifying respirator	1.6	3.3	1.5	5.8	2.0

\* Data are presented as % of respondents

**Table 2. Method and setting of silicone tube removal before the COVID-19 outbreak and during the study period (12 March 2021 to 12 May 2021)\***

Silicone tube removal	Before the COVID-19 outbreak	During the study period (12 March 2021 to 12 May 2021)
Method		
Removal from the eye rather than the nose	31.4	31.0
Tube cut at medial canthus and patient blowing it out	32.3	31.7
Direct visualization and retrieval with forceps	39.6	37.9
Endoscopic endonasal retrieval	22.5	20.9
Setting		
Operating theater	3.0	4.5
Minor treatment room	19.9	19.5
Outpatient consultation room	77.1	75.8

\* Data are presented as % of respondents

dacryoplasty (7%). 14.9% preferred both endoscopic and external DCR. Among respondents from developed countries/regions (high-income areas as defined by the World Bank<sup>21</sup>), 51.2% preferred external DCR and 36.7% preferred endoscopic DCR, whereas among respondents from non-high-income countries/regions, 64.1% preferred external DCR and 25.4% preferred endoscopic DCR ( $p<0.01$ ).

For PPE, during syringing and probing, 42.0% of respondents wore a surgical mask and 19.8% did not wear any PPE. During lacrimal surgery, 52.6% of respondents wore a surgical mask and 40.6% wore a N95 mask; 14.2% wore a face shield (Table 1). 97.7% performed silicone intubation. The proportions of respondents in terms of silicone tube removal were similar to those during the study period (Table 2).

### During the first wave of COVID-19 pandemic (Spring 2020)

For most countries, the first wave of COVID-19 pandemic was around Spring 2020. Among the respondents, 10.0% stopped all lacrimal services, 24.2% deferred all lacrimal surgery, 12.8% deferred cases at high risk of COVID-19 infection, and 36.6% provided services for acute dacryocystitis only (as an urgent indication).

## Discussion

In response to the first wave of COVID-19 pandemic in 2020, many countries implemented lockdown and social distancing measures. Most elective surgeries were suspended, including lacrimal surgeries that involve nasolacrimal duct obstruction. In a survey of lacrimal practice in Asia-Pacific published in May 2020, 57.8% of the respondents were unsure when to resume elective surgeries, and 62.8% were uncertain about the preferred screening strategy or precautionary approach prior to resuming surgeries.<sup>15</sup>

Starting from 2021, the number of new cases and deaths had decreased owing to implementation of social distancing and quarantine measures and the gradual increase in vaccination coverage.<sup>4,6</sup> However, with the emergence of Delta and Omicron variants with increased infectivity, the number of cases had risen again.

Lacrimal services of syringing and probing and nasal endoscopy involve contact with tears and the nasal mucosa, where droplets or aerosolized particles of SARS-CoV-2 can be generated. External and endoscopic endonasal DCR are often performed with mechanical tools, high speed burrs, and suction, and are considered AGMP at risk of COVID-19 spread.<sup>22</sup>

The choice to perform external DCR or endoscopic endonasal DCR largely depends on surgeon preference based on their training, experience, and equipment. In the United Kingdom in 2008, 59% of ophthalmic surgeons

had never performed endonasal DCR. In the US in 2013, 93.9% preferred external DCR, whereas in India in 2016, 86% preferred external DCR. In the Asia-Pacific region in 2017, 79.2% of surgeons preferred endoscopic DCR and 71.1% preferred external DCR.<sup>23-27</sup> In our survey, external DCR remains the preferred lacrimal surgery among lacrimal surgeons worldwide. Nonetheless, endoscopic DCR is more preferred by high-income countries than non-high-income countries (36.7% vs 25.4%). This may be due to differences in equipment, training, and expertise. A systematic review concluded that endonasal DCR and external DCR are comparable in terms of success rate.<sup>28</sup> There is no evidence to suggest whether external or endoscopic DCR is riskier in terms of spread of COVID-19. Nonetheless, endoscopic DCR involves more manipulation of the nasal mucosa than external DCR. In our survey, infection rates of countries affected the choice of DCR technique; only 26.2% preferred endoscopic DCR in countries with high infection rate, whereas 39.5% preferred so in countries with low/stable infection rate.

Lacrimal irrigation and probing are part of the basic lacrimal assessment and a potential source of aerosol generation. The presence of SARS-CoV-2 in tears and conjunctival secretion highlights the potential risk.<sup>29</sup> Some guidelines recommend the use of low-capacity syringes and 25 or 27 G cannulas to minimize the force generated during the procedure, and the use of adequate PPE for syringing and probing.<sup>19</sup> In our survey, the proportion of respondents who did not wear any PPE decreased from 19.8% before the COVID-19 outbreak to 4.7% during the study period ( $p<0.01$ ). Similarly, for syringing and probing, the proportion of respondents who wore a N95 mask and a face shield increased from 35.7% and 15.4%, respectively, before the COVID-19 outbreak to 49.5% and 24.9%, respectively, during the study period ( $p<0.01$ ). Syringing and probing is a potential AGMP and thus adequate protection is warranted. Wearing a surgical mask has become a basic requirement in clinics and hospitals to reduce transmission through direct inhalation in close proximity.<sup>11,16,22</sup>

Nasal endoscopy is useful in preoperative assessment and postoperative management of endoscopic DCR. Nasal endoscopy is an AGMP, as it involves suction and intranasal manipulations.<sup>9,22</sup> In our survey, during the study period, 37.3% and 54.6% of respondents wore a surgical mask and a N95 mask, respectively, and 27.8% also wore a face shield. Most respondents wore PPE during nasal endoscopy, consistent with guidelines on AGMPs.

For lacrimal surgery, respondents had shifted from wearing a surgical mask alone (49.1% to 32.7%) to wearing a N95 mask (40.6% to 55.1%) and a face shield (14.2% to 24.3%) [ $p<0.01$ ] since the pandemic. Although surgical masks are good protection against droplet transmission, N95 masks are more effective in blocking infective aerosols. Face shields and goggles are recommended for additional protection.<sup>22</sup> During the pandemic, higher levels of PPE are necessary when performing lacrimal surgery.

During the study period, 89.3% of respondents performed preoperative testing for SARS-CoV-2 for patients. However, preoperative viral testing has limited sensitivity, especially in asymptomatic or pre-symptomatic persons. Therefore, surgeons should put on appropriate PPE, adjusting for the risk of surgery, prevalence of COVID-19 in the community, and availability of PPE. Lacrimal surgery is a potential AGMP; it is recommended to wear a N95 mask, a face shield/goggles, and a water-impermeable gown even if the patient is tested negative, especially when local infection rates are high.<sup>9</sup>

During the study period, 95.1% of respondents performed silicone intubation. The use of silicone stents results in a higher success rate of DCR.<sup>30-32</sup> 73.5% of surgeons in the Asia-Pacific region and 75% to 100% of surgeons in the United Kingdom performed silicone intubation.<sup>25,27</sup>

One limitation to this survey was potential recall bias, particularly with respect to questions about the early pandemic period. In addition, the effect of vaccination was not assessed (because the vaccination program had just been begun during the study period), as were preoperative application of povidone iodine on nasal mucosa, detailed surgical steps, equipment used (for suction or irrigation, bone drills, cautery), lacrimal surgical training, and telemedicine so as to keep the questionnaire brief.

## Conclusion

Aerosolized spread of viral particles during AGMP should be minimized while performing lacrimal services. With the experience gained from the COVID-19 pandemic, orbital and lacrimal surgeons are better prepared to face future novel viral strains.

## Contributors

All authors designed the study, acquired the data, analyzed the data, drafted the manuscript, and critically revised the manuscript for important intellectual content. All authors had full access to the data, contributed to the study, approved the final version for publication, and take responsibility for its accuracy and integrity.

## Conflicts of interest

All authors have disclosed no conflicts of interest.

## Funding/support

This study received no specific grant from any funding agency in the public, commercial, or not-for-profit sectors.

## Data availability

All data generated or analyzed during the present study are available from the corresponding author on reasonable request.

## Ethics approval

The study was approved by the Kowloon Central / Kowloon East Cluster Research Ethics Committee (Reference: KC/KE-21-0160/ER-3).

## Acknowledgements

We would like to thank clinicians who took time to complete the survey and the national and international oculoplastic societies who helped distribute the survey link to their members.

## References

- Harrison AG, Lin T, Wang P. Mechanisms of SARS-CoV-2 transmission and pathogenesis. *Trends Immunol* 2020;41:1100-15. [Crossref](#)
- Parasher A. COVID-19: Current understanding of its pathophysiology, clinical presentation and treatment. *Postgrad Med J* 2021;97:312-20. [Crossref](#)
- Wang D, Hu B, Hu C, et al. Clinical characteristics of 138 hospitalized patients with 2019 novel coronavirus-infected pneumonia in Wuhan, China. *JAMA* 2020;323:1061-9. [Crossref](#)
- World Health Organization. Coronavirus Disease (COVID-2019) Situation Reports. 2020. Available at: <https://www.who.int/emergencies/diseases/novel-coronavirus-2019>. Accessed 13 March 2022.
- Tang JW, Marr LC, Li Y, Dancer SJ. Covid-19 has redefined airborne transmission. *BMJ* 2021;373:n913. [Crossref](#)
- World Health Organization. Available at: <https://www.who.int/news-room/questions-and-answers/item/coronavirus-disease-covid-19-how-is-it-transmitted>. Accessed 13 March 2022.
- Workman AD, Jafari A, Welling DB, et al. Airborne aerosol generation during endonasal procedures in the era of COVID-19: risks and recommendations. *Otolaryngol Head Neck Surg* 2020;163:465-70. [Crossref](#)
- Mick P, Murphy R. Aerosol-generating otolaryngology procedures and the need for enhanced PPE during the COVID-19 pandemic: a literature review. *J Otolaryngol Head Neck Surg* 2020;49:29. [Crossref](#)
- Lammers MJW, Lea J, Westerberg BD. Guidance for otolaryngology health care workers performing aerosol generating medical procedures during the COVID-19 pandemic. *J Otolaryngol Head Neck Surg* 2020;49:36. [Crossref](#)
- Tan L, Kovoov JG, Williamson P, et al. Personal protective equipment and evidence-based advice for surgical departments during COVID-19. *ANZ J Surg* 2020;90:1566-72. [Crossref](#)
- Revised guidelines for potential aerosol-generating procedures (AGPs) within the ENT clinic. 2021. Available at: [https://www.entuk.org/\\_userfiles/pages/files/covid19/revised\\_agp\\_guidelines.pdf](https://www.entuk.org/_userfiles/pages/files/covid19/revised_agp_guidelines.pdf)
- Ali MJ. COVID-19 pandemic and lacrimal practice: multipronged resumption strategies and getting back on our feet. *Indian J Ophthalmol* 2020;68:1292-9. [Crossref](#)



13. Mak ST, Yuen HK. Oculoplastic surgery practice during the COVID-19 novel coronavirus pandemic: experience sharing from Hong Kong. *Orbit* 2020;39:316-8. [Crossref](#)
14. Lanni V, Iuliano A, Laezza MP, Uccello G, Tranfa F, Strianese D. Oculoplastic management of patients in the Covid-19 era: experience from an Italian tertiary referral center. *Orbit* 2020;39:391-3. [Crossref](#)
15. Nair AG, Narayanan N, Ali MJ. A survey on the impact of COVID-19 on lacrimal surgery: the Asia-Pacific perspective. *Clin Ophthalmol* 2020;14:3789-99. [Crossref](#)
16. Nguyen AX, Gervasio KA, Wu AY. COVID-19 recommendations from ophthalmic and plastic reconstructive surgery societies worldwide. *Ophthalmic Plast Reconstr Surg* 2020;36:334-45. [Crossref](#)
17. Quaranta-Leoni FM, Paridaens D, Verity D. European Society of Ophthalmic Plastic and Reconstructive Surgery (ESOPRS) recommendations for oculoplastic surgeons during the COVID-19 pandemic: a challenge for the future. *Orbit* 2020;39:460-2. [Crossref](#)
18. American Academy of Ophthalmology. List of urgent and emergent ophthalmic procedures. Available at: <https://www.aao.org/headline/list-of-urgent-emergent-ophthalmic-procedures>.
19. Ali MJ, Hegde R, Nair AG, et al. All India Ophthalmological Society–Oculoplastics Association of India consensus statement on preferred practices in oculoplasty and lacrimal surgery during the COVID-19 pandemic. *Indian J Ophthalmol* 2020;68:974-80. [Crossref](#)
20. Nair AG, Gandhi RA, Natarajan S. Effect of COVID-19 related lockdown on ophthalmic practice and patient care in India: results of a survey. *Indian J Ophthalmol* 2020;68:725-30. [Crossref](#)
21. The World Bank. Available at: <https://www.worldbank.org/en/home>
22. Daigle P, Leung V, Yin V, Kalin-Hajdu E, Nijhawan N. Personal protective equipment (PPE) during the COVID-19 pandemic for oculo-facial plastic and orbital surgery. *Orbit* 2021;40:281-6. [Crossref](#)
23. Barmettler A, Ehrlich JR, Lelli G Jr. Current preferences and reported success rates in dacryocystorhinostomy amongst ASOPRS members. *Orbit* 2013;32:20-6. [Crossref](#)
24. Nair AG, Kamal S, Agarwal A. Indian survey on practice patterns of lacrimal and eyelid disorders (iSUPPLE): report 2: mitomycin-C and lacrimal stents in dacryocystorhinostomy. *J Craniofac Surg* 2016;27:2015-9. [Crossref](#)
25. Gauba V, Islam T, Saleh GM, Zuberbuhler B, Vize C. The practice of dacryocystorhinostomy (DCR) surgery by ophthalmologists in the United Kingdom (UK). *Orbit* 2008;27:279-83. [Crossref](#)
26. Huang J, Malek J, Chin D, et al. Systematic review and meta-analysis on outcomes for endoscopic versus external dacryocystorhinostomy. *Orbit* 2014;33:81-90. [Crossref](#)
27. Kwok T, Ali MJ, Yuen H. Preferred practice patterns in endoscopic dacryocystorhinostomy among oculoplastic surgeons in Asia-Pacific region. *Orbit* 2018;37:248-53. [Crossref](#)
28. Sobel RK, Aakalu VK, Wladis EJ, Bilyk JR, Yen MT, Mawn LA. A comparison of endonasal dacryocystorhinostomy and external dacryocystorhinostomy: a report by the American Academy of Ophthalmology. *Ophthalmology* 2019;126:1580-5. [Crossref](#)
29. Hu Y, Chen T, Liu M, et al. Positive detection of SARS-CoV-2 combined HSV1 and HHV6B virus nucleic acid in tear and conjunctival secretions of a non-conjunctivitis COVID-19 patient with obstruction of common lacrimal duct. *Acta Ophthalmol* 2020;98:859-63. [Crossref](#)
30. Kang MG, Shim WS, Shin DK, Kim JY, Lee JE, Jung HJ. A systematic review of benefit of silicone intubation in endoscopic dacryocystorhinostomy. *Clin Exp Otorhinolaryngol* 2018;11:81-8. [Crossref](#)
31. Feng YF, Cai JQ, Zhang JY, Han XH. A meta-analysis of primary dacryocystorhinostomy with and without silicone intubation. *Can J Ophthalmol* 2011;46:521-7. [Crossref](#)
32. Fayers T, Dolman PJ. Bicanalicular silicone stents in endonasal dacryocystorhinostomy: results of a randomized clinical trial. *Ophthalmology* 2016;123:2255-9. [Crossref](#)