

Intraosseous hemangioma at the left lateral canthus: a case report

Julia YY Chan, MBBS, Hunter KL Yuen, FRCSEd, FCOphthHK

Department of Ophthalmology and Visual Sciences, The Chinese University of Hong Kong, Hong Kong

Correspondence and reprint requests:

Dr Julia YY Chan, Hong Kong Eye Hospital, 147K Argyle Street, Kowloon, Hong Kong.

Email: cyyj717@gmail.com

Abstract

A 56-year-old Chinese woman presented with a 7-year history of a progressive, painless swelling at the left lateral canthus. Contrast-enhanced computed tomography (CT) of the orbit revealed a hypodense lesion of 1.4 cm at the anterior aspect of the left zygomatic arch. A radiological diagnosis of fibrous dysplasia was made. Debulking of the left lateral wall was performed. Intraoperatively, a diamond burr was used to smooth the surface and resulted in moderate bleeding, which was uncommon for fibrous dysplasia. Hemostasis was achieved with bone wax and direct compression. The pathological diagnosis was an intraosseous hemangioma.

Case Report

In October 2014, a 56-year-old Chinese woman presented with a 7-year history of a progressive, painless swelling at the left lateral canthus. Clinical examination revealed a non-tender mass with firm attachment at its base, of firm-to-hard consistency with no overlying skin change. Ophthalmic and neurological examination was unremarkable. Contrast-enhanced computed tomography (CT) of the orbit revealed a hypodense lesion of 1.4 cm at the anterior aspect of the left zygomatic arch, near the lateral wall of the left orbit (**Figure 1**). A radiological diagnosis of fibrous dysplasia was made.

In July 2017, debulking of the left lateral orbital wall was performed. Intraoperatively, an elevated lesion adhering to the lateral orbital rim was seen. A diamond burr was used to smooth its surface and resulted in moderate bleeding,

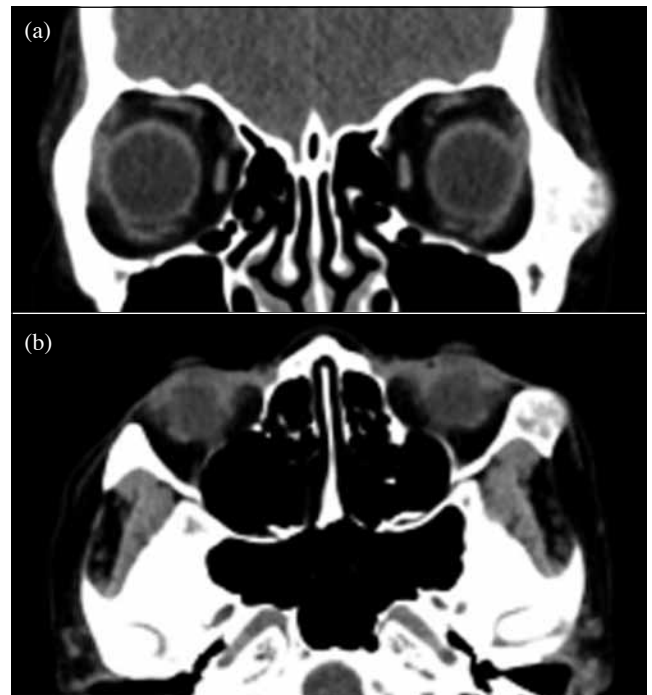


Figure 1. (a) Coronal and (b) axial contrast-enhanced computed tomographic scans of the orbit showing a well-circumscribed hypodense lesion at the anterior aspect of the left zygomatic arch with a sunburst and honeycomb appearance, near the lateral wall of the left orbit.

which was uncommon for fibrous dysplasia. Hemostasis was achieved with bone wax and direct compression (**Figure 2**). The specimen was sent for pathological examination. Microscopy revealed medium-sized and dilated blood vessels lined with benign endothelium with poorly formed thin muscle coat in the stroma with reactive bones at the periphery. The pathological diagnosis was an intraosseous hemangioma at the left lateral orbital wall.

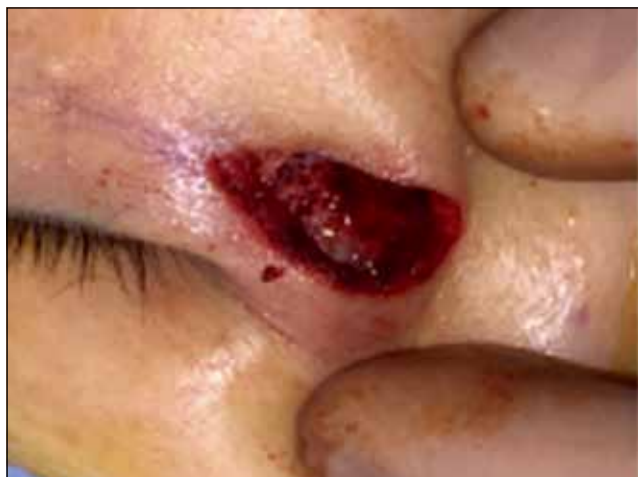

Figure 2. Hemostasis is achieved with bone wax and direct compression.

Discussion

Intraosseous hemangioma is rare and accounts for <1% of all bony tumors; its incidence is 2- to 3-fold higher in women than men.¹ Orbital intraosseous hemangiomas most commonly occur superiorly (35.3%) and inferolaterally (23.5%); only 5.9% occur laterally, as in our case.² Although

the lesion is slow-growing and non-tender, posterior extension to the middle cranial fossa may cause a significant pressure effect with consequent vision loss, diplopia, or proptosis. On CT, the hypodense lytic configuration has a ‘sunburst’ or ‘honeycomb’ appearance. In our patient, retrospective review of the CT scans demonstrated the sunray pattern of trabeculation with well-circumscribed rarefaction (Figure 1). This made the diagnosis of intraosseous hemangioma probable.

Differential diagnoses of intraosseous hemangioma, in addition to fibrous dysplasia, include lytic bone lesions such as aneurysmal bone cyst, giant cell tumor, Langerhans cell histiocytosis, and osteogenic sarcoma.³ Biopsy is essential to establish the diagnosis. The mainstay of treatment is *en bloc* excision with a small bone margin, with particular care to achieve hemostasis as the lesion is highly vascular. In our patient, hemostasis was achieved with bone wax and direct compression. Preoperative embolization is advocated if severe bleeding is expected.⁴ In patients who are unfit for surgery or in lesions that are difficult to access, radiotherapy can be an alternative.⁵ Recurrence after *en bloc* excision is uncommon.

Declaration

The authors have no conflicts of interest to disclose.

References

1. Sweet C, Silbergleit R, Mehta B. Primary intraosseous hemangioma of the orbit: CT and MR appearance. *AJNR Am J Neuroradiol*. 1997;18:379-81.
2. Rios Dias GD, Velasco Cruz AA. Intraosseous hemangioma of the lateral orbital wall. *Ophthalmic Plast Reconstr Surg*. 2004;20:27-30. [crossref](#)
3. Relf SJ, Bartley GB, Unni KK. Primary orbital intraosseous hemangioma. *Ophthalmology*. 1991;98:541-7. [crossref](#)
4. Zucker JJ, Levine MR, Chu A. Primary intraosseous hemangioma of the orbit. Report of a case and review of literature. *Ophthalmic Plast Reconstr Surg*. 1989;5:247-55. [crossref](#)
5. Banerji D, Inao S, Sugita K, Kaur A, Chhabra DK. Primary intraosseous orbital hemangioma: a case report and review of the literature. *Neurosurgery*. 1994;35:1131-4. [crossref](#)