ORIGINAL ARTICLE

A combination of pars plana vitrectomy, inverted internal limiting membrane flap technique and intraocular gas tamponade for macular hole–induced retinal detachment

Byron TH Chu,[1,2] FCOphthHK, FHKAM, Susanna WS Tsang,[2] MRCSEd, MBChB, Can YF Yuen,[2] FCOphthHK, FHKAM

[1]*Eye Clinic, HKSAR, China*

[2]*Department of Ophthalmology, Caritas Medical Centre, HKSAR, China*

Correspondence and reprint requests:

Dr. Byron TH Chu, Eye Clinic, Shop 7, 1/F Tung Yik Building, 8 Yu King Square, Yuen Long, New Territories, HKSAR, China.

Email: drchu999@gmail.com

Abstract

Purpose: To evaluate the outcome of a combination of pars plana vitrectomy (PPV), inverted internal limiting membrane (ILM) flap technique and intraocular gas tamponade for macular hole–induced retinal detachment (MHRD).

Methods: Medical records of 3 men and 12 women aged 39 to 83 years who underwent PPV with inverted ILM flap technique and intraocular gas tamponade for MHRD by a single vitreoretinal surgeon were retrospectively reviewed. Outcome was evaluated with fundus examination and spectral domain optical coherence tomography. Primary outcome measures were retinal reattachment rate, macular hole closure rate and improvement in best-corrected visual acuity (BCVA). Secondary outcome measures included subjective improvement in central scotoma or metamorphopsia. The Kaplan-Meier survival curve was analyzed with non-closure of the macular hole as the end point.

Results: The retinal reattachment rate was 100%. The rate of macular hole closure was 73.3%. The mean ± SD BCVA improved from 1.73 ± 0.69 to 1.16 ± 0.51 logMAR ($p < 0.05$). All eyes had subjective improvement in scotoma and metamorphopsia. The survival rate was 86.7% at 6 months, 74.3% at 12 months, and 74.3% at 16 months. The median survival time was 18 months. No re-opening of closed macular hole or retinal re-detachment was detected. No complications such as retinal tear, retinal detachment elsewhere, persistently elevated intraocular pressure, or endophthalmitis occurred.

Conclusion: A combination of PPV, inverted ILM flap technique and intraocular gas tamponade is an effective surgical option for MHRD.

Key words: Retinal detachment; Retinal perforations

Introduction

Macular hole–induced retinal detachment (MHRD) can result in vision loss. The pathogenesis of macular hole formation is related to vitreo-macular tangential traction and perifoveal vitreous detachment.[1,2] Axial length elongation and posterior staphyloma formation may contribute to subsequent retinal detachment.[3,4]

Surgery for MHRD is challenging due to the complex pathogenesis. Pars plana vitrectomy (PPV) is a well-established method for the treatment of macular hole with or without retinal detachment.[5] Various surgical procedures have been proposed to improve macular hole closure and retinal reattachment rate, including removal of epiretinal membrane, removal of internal limiting membrane (ILM), endolaser photocoagulation around macular hole, intraocular gas and silicone oil tamponade.[6-10]

The inverted ILM flap technique has been shown to improve both anatomic and functional success rates for large (>400 µm) macular hole closure.[11] This study evaluated the outcome of PPV with inverted ILM flap technique and intraocular gas tamponade for MHRD.

Methods

This study was approved by the Research Ethics Committee of Kowloon West Cluster of the Hong Kong Hospital Authority. Medical records of 3 men and 12 women aged 39 to 83 (mean ± standard deviation [SD], 63.5 ± 11.9) years who underwent PPV with inverted ILM flap technique and intraocular gas tamponade for MHRD by a single vitreoretinal surgeon at the Department of Ophthalmology, Caritas Medical Centre, from 1 July 2014 to 31 December 2015 were retrospectively reviewed. Exclusion criteria included concurrent retinal pathology affecting visual acuity such as age-related macular degeneration, retinal vascular occlusions, recurrent MHRD, history of PPV, and follow-up <6 months.

A posterior vitreous detachment was first created followed by complete PPV using a 23-gauge or 25-gauge microincision. Sub-retinal fluid was drained through the macular hole. Brilliant blue G 0.025% combined with 4% polyethylene glycol stain was used to facilitate visualization of the ILM. During ILM circumferential peeling, the central one disc diameter ILM was not removed completely from the retina but was left attached to the edge of the macular hole. The ILM was then gently flipped over the macular hole from all sides using intraocular forceps until the ILM became inverted and covered the entire base of the macular hole. The remaining ILM was peeled circumferentially for up to 4 disc diameter. Fluid-gas exchange was performed with 12% octafluoropropane. Cataract surgery and intraocular lens implantation were performed simultaneously in patients with cataract. Patients were instructed to maintain a prone position for at least 2 weeks.

Spectral domain optical coherence tomography was performed at every follow-up. Primary outcome measures were retinal reattachment rate, macular hole closure rate and improvement in best-corrected visual acuity (BCVA). Secondary outcome measures included subjective improvement in central scotoma or metamorphopsia based on Amsler grid testing.

BCVA was converted to the logarithm of the minimal angle of resolution (logMAR). The BCVA of counting fingers or hand movements was assigned as the equivalent Snellen acuity of 20/2000 or 20/20000, respectively.[12] Pre- and post-operative BCVA (logMAR) was compared using the paired *t*-test. A p value of <0.05 was considered statistically significant. The Kaplan-Meier survival curve was analyzed with non-closure of the macular hole as the end point.

Results

The mean ± SD axial length of the eye was 27.9 ± 2.65 mm (**Table**); 11 of the 15 eyes (73.3%) had high myopia with an axial length >26.5 mm. The mean ± SD follow-up duration was 12.3 ± 5.0 months.

The retinal reattachment rate was 100%. The rate of macular hole closure was 73.3%, based on spectral domain optical coherence tomography (**Figure 1**). The mean ± SD BCVA improved from 1.73 ± 0.69 to 1.16 ± 0.51 logMAR ($p < 0.05$). All eyes had subjective improvement in scotoma and metamorphopsia. The survival rate was 86.7% at 6 months, 74.3% at 12 months, and 74.3% at 16 months (**Figure 2**). The median survival time was 18 months. No re-opening of closed macular hole or retinal re-detachment was detected. No complications such as retinal tear, retinal detachment elsewhere, persistently elevated intraocular pressure, or endophthalmitis occurred.

Discussion

MHRD accounts for 0.5% of all retinal detachments.[13] It occurs predominantly in highly myopic eyes and is highly prevalent in East Asia.[14-16] MHRD is considered to be caused by anteroposterior vitreous traction on the posterior pole secondary to a posterior staphyloma, tangential traction on the macular from contraction of the cortical vitreous and membranes, and the presence of atrophy of the retinal pigment epithelium and choroid.[2-4,6]

Table. Baseline characteristics.

Characteristics	Data
No. of males: females	3:12
Mean ± SD (range) age (years)	63.5 ± 11.9 (39-83)
Mean ± SD best corrected visual acuity (logMAR)	1.73 ± 0.69
Mean ± SD axial length (mm)	27.9 ± 2.65
No. of phakic: pseudophakic lens	10:5

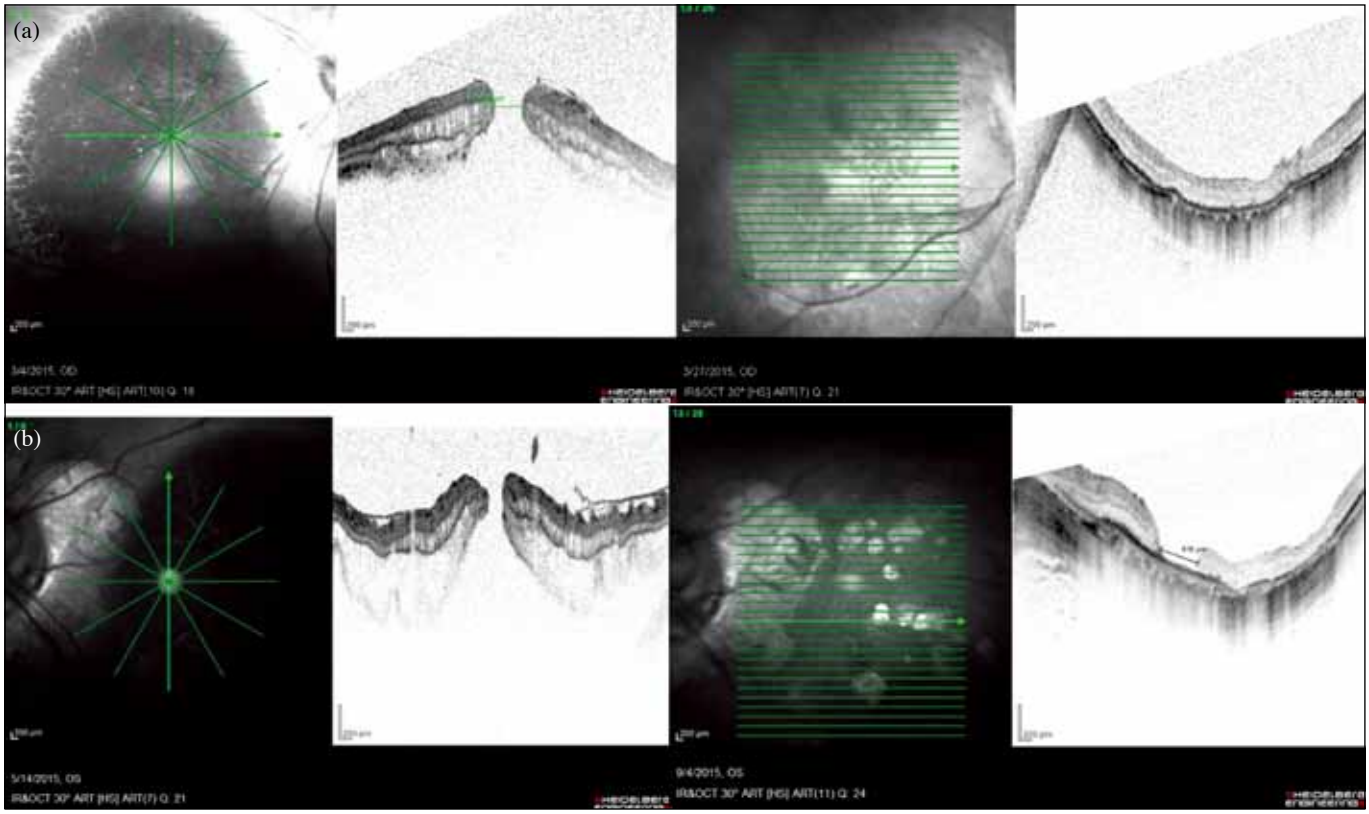

Figure 1. Pre- and post-operative optical coherence tomography of an eye with macular hole–induced retinal detachment showing (a) retinal reattachment and macula hole closure, (b) retinal reattachment but the macular hole remains flat open.

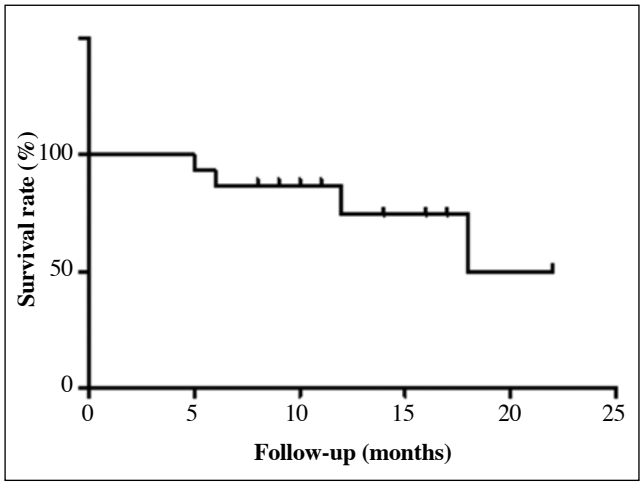

Figure 2. Kaplan-Meier survival curve showing a survival rate of 86.7% at 6 months, 74.3% at 12 months, and 74.3% at 16 months. The median survival time was 18 months. No re-opening of closed macular hole or retinal re-detachment was detected.

Surgical procedures for MHRD include macular buckle, PPV, intraocular gas tamponade, silicone oil tamponade, ILM peeling, and a combination of these approaches.[6-10] A combination of PPV, peeling of ILM, and gas tamponade is most frequently used.[6,17,18] This approach is based on the concept that perifoveal vitreous contraction and cellular components on the surface of the ILM play a role in the development of MHRD. By removing the ILM, it is expected that total removal of the overlying epiretinal membrane and cellular constituents will result in complete relief of the tangential traction.[19-21] This approach has increased the retinal reattachment rate from 85% to 91%.[7,22] Nonetheless, failure of macular hole closure remains high in MHRD, ranging from 30% to 52%.[22,23]

The inverted ILM flap technique for treating a macular hole improves both anatomic and functional outcome.[11] It was hypothesized that proliferation of glial cells is stimulated by the inverted ILM flap technique, as it produces an environment conducive to the movement of photoreceptors into direct proximity to the fovea, thereby enhancing macular hole closure.[11] Our inverted ILM flap technique differs slightly to the original technique.[11] The peripheral ILM was not trimmed; instead a larger area (up to four disc diameter) of peripheral ILM was peeled circumferentially.

Our surgical technique achieved a 100% retinal reattachment rate and a 73% macular hole closure rate, which is higher than the widely used method of complete ILM removal and gas tamponade. All patients had subjective improvement in scotoma and metamorphopsia. This could be explained

by the reattachment of 'peripheral macula', leaving only a central foveal full thickness defect. Our favorable outcome may support the hypothesis that photoreceptor repositioning at the fovea is aided by the ILM flap.[7,24] Peeling of a larger area (up to 4 disc diameter) of ILM enabled complete relief of tangential traction, and may have contributed to the improved macular hole closure rate.

Our study was limited by the small sample size and retrospective nature. A multivariate study with a larger number of patients is needed to confirm our findings.

Conclusion

PPV combined with inverted ILM flap technique and intraocular gas tamponade is an effective surgical option for MHRD. The approach achieved an excellent reattachment rate, high macular hole closure rate, and symptomatic improvement.

Declaration

All authors have disclosed no conflicts of interest.

References

1. *Gass JD. Idiopathic senile macular hole. Its early stages and pathogenesis. Arch Ophthalmol 1988;106:629-39.*
2. *Stirpe M, Michels RG. Retinal detachment in highly myopic eyes due to macular holes and epiretinal traction. Retina 1990;10:113-4.*
3. *Morita H, Ideta H, Ito K, Yonemoto J, Sasaki K, Tanaka S. Causative factors of retinal detachment in macular holes. Retina 1991;11:281-4.*
4. *Akiba J, Konno S, Yoshida A. Retinal detachment associated with a macular hole in severely myopic eyes. Am J Ophthalmol 1999;128:654-5.*
5. *Benson WE, Cruickshanks KC, Fong DS, et al. Surgical management of macular holes: a report by the American Academy of Ophthalmology. Ophthalmology 2001;108:1328-35.*
6. *Oshima Y, Ikuno Y, Motokura M, Nakae K, Tano Y. Complete epiretinal membrane separation in highly myopic eyes with retinal detachment resulting from a macular hole. Am J Ophthalmol 1998;126:669-76.*
7. *Kadonosono K, Yazama F, Itoh N, et al. Treatment of retinal detachment resulting from myopic macular hole with internal limiting membrane removal. Am J Ophthalmol 2001;131:203-7.*
8. *Uemoto R, Yamamoto S, Tsukahara I, Takeuchi S. Efficacy of internal limiting membrane removal for retinal detachments resulting from a myopic macular hole. Retina 2004;24:560-6.*
9. *Kwok AK, Cheng LL, Gopal L, Sharma T, Lam DS. Endolaser around macular hole in the management of associated retinal detachment in highly myopic eyes. Retina 2000;20:439-44.*
10. *Scholda C, Wirtitsch M, Biowski R, Stur M. Primary silicone oil tamponade without retinopexy in highly myopic eyes with central macular hole detachments. Retina 2005;25:141-6.*
11. *Michalewska Z, Michalewski J, Adelman RA, Nawrocki J. Inverted internal limiting membrane flap technique for large macular holes. Ophthalmology 2010;117:2018-25.*
12. *Holladay JT. Proper method for calculating average visual acuity. J Refract Surg 1997;13:388-91.*
13. *Margherio RR, Schepens CL. Macular breaks. 2. Management. Am J Ophthalmol 1972;74:233-40.*
14. *Wong TY, Ferreira A, Hughes R, Carter G, Mitchell P. Epidemiology and disease burden of pathologic myopia and myopic choroidal neovascularization: an evidence-based systematic review. Am J Ophthalmol 2014;157:9-25.*
15. *Wojciechowski R. Nature and nurture: the complex genetics of myopia and refractive error. Clin Genet 2011;79:301-20.*
16. *Zhang CF, Hu C. High incidence of retinal detachment secondary to macular hole in a Chinese population. Am J Ophthalmol 1982;94:817-9.*
17. *Ichibe M, Yoshizawa T, Murakami K, et al. Surgical management of retinal detachment associated with myopic macular hole: anatomic and functional status of the macula. Am J Ophthalmol 2003;136:277-84.*
18. *Ripandelli G, Parisi V, Friberg TR, Coppé AM, Scassa C, Stirpe M. Retinal detachment associated with macular hole in high myopia: using the vitreous anatomy to optimize the surgical approach. Ophthalmology 2004;111:726-31.*
19. *Funata M, Wendel RT, de la Cruz Z, Green WR. Clinicopathologic study of bilateral macular holes treated with pars plana vitrectomy and gas tamponade. Retina 1992;12:289-98.*
20. *Madreperla SA, Geiger GL, Funata M, de la Cruz Z, Green WR. Clinicopathologic correlation of a macular hole treated by cortical vitreous peeling and gas tamponade. Ophthalmology 1994;101:682-6.*
21. *Almony A, Nudleman E, Shah GK, et al. Techniques, rationale, and outcomes of internal limiting membrane peeling. Retina 2012;32:877-91.*
22. *Nadal J, Verdaguer P, Canut MI. Treatment of retinal detachment secondary to macular hole in high myopia: vitrectomy with dissection of the inner limiting membrane to the edge of the staphyloma and long-term tamponade. Retina 2012;32:1525-30.*
23. *Ikuno Y, Sayanagi K, Oshima T, et al. Optical coherence tomographic findings of macular holes and retinal detachment after vitrectomy in highly myopic eyes. Am J Ophthalmol 2003;136:477-81.*
24. *Kuriyama S, Hayashi H, Jingami Y, Kuramoto N, Akita J, Matsumoto M. Efficacy of inverted internal limiting membrane flap technique for the treatment of macular hole in high myopia. Am J Ophthalmol 2013;156:125-31.*