

Sutureless vitrectomy: techniques of self-sealing sclerotomies

Alvin K. H. Kwok,¹ MBBS, FRCS, John C. Chen,² MD, FRCSC

¹Senior Medical Officer, Department of Ophthalmology & Visual Sciences,

The Chinese University of Hong Kong, Prince of Wales Hospital, Shatin, Hong Kong.

²Associate Professor, Department of Ophthalmology, McGill University, Montreal, Quebec, Canada.

Correspondence:

Alvin K.H. Kwok, MBBS, FRCS, Department of Ophthalmology & Visual Sciences,

The Chinese University of Hong Kong, Prince of Wales Hospital, Shatin, Hong Kong.

Abstract

Different techniques of creating self-sealing *pars plana* sclerotomies are described. This type of wound construction has many advantages. Sudden change of intraocular pressure during operation is reduced, which in turn minimizes the ensuing complications like intraoperative bleeding, retinal and vitreous herniation. Operative time is reduced. Suture problems are avoided. Further modification of the techniques to prevent potential complications is discussed.

Key words: Sutureless, Vitrectomy, Self-sealing, Sclerotomy

Techniques of self-sealing sclerotomies in *pars plana* vitrectomy

In standard *pars plana* vitrectomy, three sclerotomy incisions are usually prepared. In adults, these sclerotomies are generally placed in the anterior *pars plana*. Depending on the phakic status of the eye, they are placed 3 to 4mm posterior to the limbus. These sclerotomies are usually done using a disposable 20-gauge microvitrectoretinal (MVR) blade directed perpendicular to the sclera at the inferotemporal, superotemporal, and superonasal quadrants. The inferotemporal sclerotomy site is usually used for the placement of an infusion cannula. Vitrectomy instruments are introduced through the 2 superior sclerotomy sites.

During insertion or exchange of intraocular instruments, there can be marked fluctuation of intraocular pressure especially in those situations when the vitreous gel is not plugging the posterior scleral lips. The use of a silicone strip which was secured to the underlying sclera over the sclerotomy sites has been recommended to prevent fluid

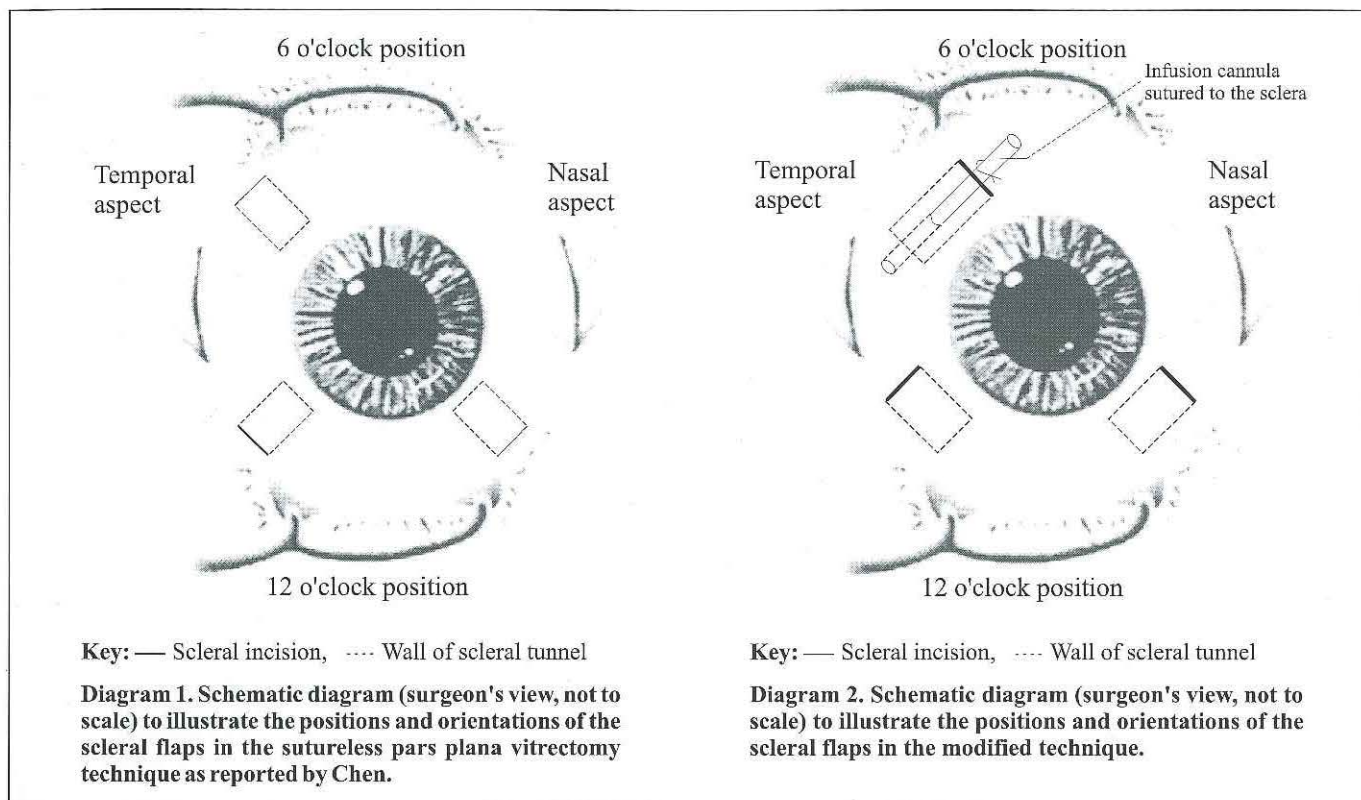
leakage.¹ However, at the end of the operation, these sclerotomy sites still require closure, usually with an 7-O or 8-O suture. It is sometimes difficult to achieve watertight closure, despite lowering the intraocular pressure temporarily before tying the knot. This problem is more common when braided, absorbable suture material is used. Some surgeons recommend using a monofilament suture in a shoelace fashion.² However, it may be difficult to bury the knot of an 8-0 nylon suture, especially with the shoelace type of closure. Unless buried, the nonabsorbable monofilament suture ends frequently protrude through the conjunctiva and cause irritation, requiring postoperative removal of the suture. Sutures-related conjunctival pigmentation can also poses a cosmetic problem. After removal of the infusion cannula at the end of surgery, maintenance of intraocular pressure can be troublesome during the closure of the inferotemporal sclerotomy.

To overcome these problems, two methods of creating sclerotomies have been devised, which enable the closure watertight without suturing. Intraocular pressure control is maintained throughout the procedure.

Surgical Technique 1

One of the authors (Chen JC) devised a new method of creating *pars plana* sclerotomies in vitrectomy procedures.³ After conjunctival peritomy, sclerotomy incisions are created in the inferotemporal, superotemporal, and superonasal quadrants as illustrated in **Diagram 1**.

A 2 mm half-depth scleral incision is created using an angled, bevel-up blade (Crescent Knife®, Alcon Laboratories Inc, Fort Worth, Tex) with its sharp, advancing edge directed perpendicular to the scleral surface 2mm posterior to the intended site of entry. For example, in an aphakic eye in which the intended sclerotomy entry is 3mm posterior to the limbus, this incision will be made 5mm posterior to the



limbus (Figure 1). With the same crescent knife, a tunnel incision is then made toward the limbus to create a scleral flap. This tunneling dissection is carried to a point slightly anterior to the site of intended entry (Figure 2). With the scleral flap retracted anteriorly, a MVR blade (V-Lance, Alcon Surgical) is then used to enter the vitreous cavity perpendicular to the scleral surface 3 or 4mm posterior to the limbus (Figure 3).

The inferotemporal sclerotomy site is used for the infusion cannula. In an eye in which the crystalline lens has been or will be removed, the infusion cannula may be left unsecured. However, in a phakic eye in which the lens is to be preserved, the cannula should be secured with a mattress suture to prevent it from rotating anteriorly and damaging the lens.

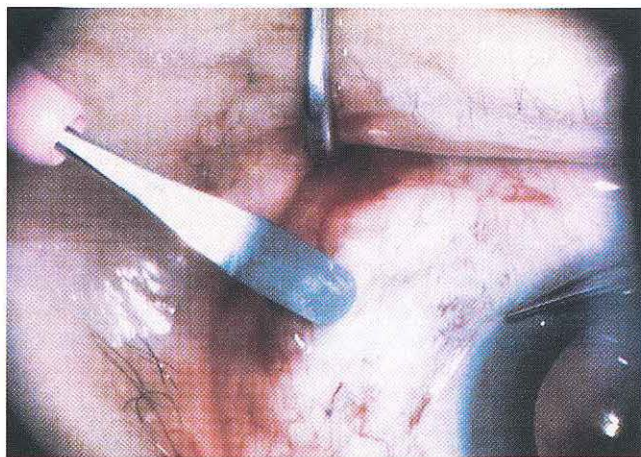


Figure 1. A partial thickness scleral incision is fashioned with the cutting edge of the crescent knife held perpendicular to the surface of globe. (Surgeon's view, inferotemporal sclerotomy)

Surgical Technique 2

Small interpalpebral space is not uncommon in Asian eyes. It may be difficult or not feasible to create the scleral pocket. This is because the initial scleral incision has to be placed about 5-6 mm posterior to the limbus, in contrast to the 3-4 mm in conventional sclerotomies. Moreover, the tip of the infusion cannula may hit the lens as it is tilted anteriorly by the scleral tunnel flap. We overcome these difficulties by rotating the initial 2 mm long scleral tunnel 90 degrees away from the original method, making it radial to the limbus (Diagram 2). The entrance of the incision remains 3-4 mm from the limbus.

A 2 mm half-depth scleral incision is created using an angled,

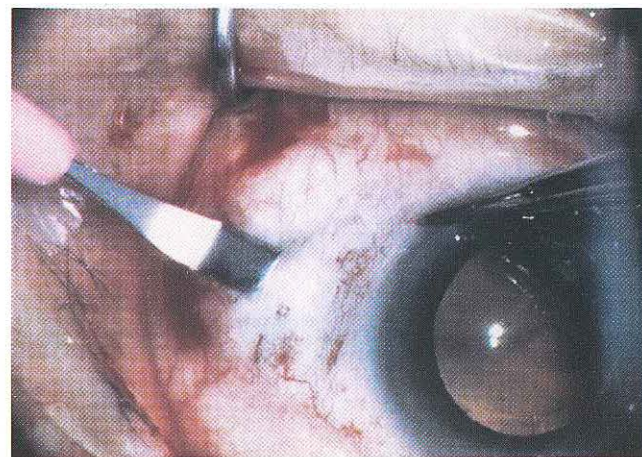


Figure 2. A scleral tunnel incision of 2mm long is made by advancing the crescent knife towards the limbus. (Surgeon's view, inferotemporal sclerotomy)

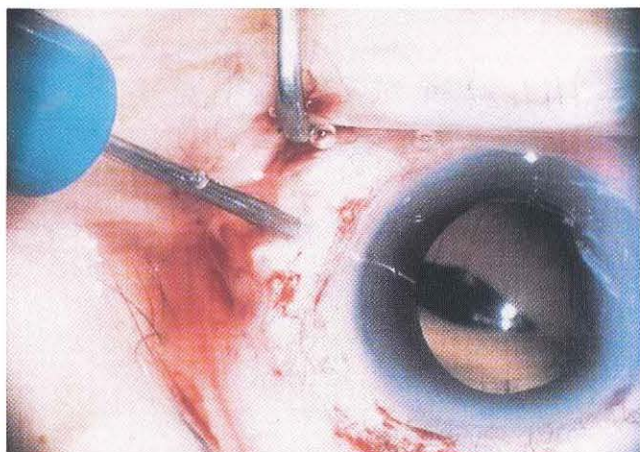


Figure 3. A microvitrectomy blade is used to retract the scleral flap and puncture the globe at the *pars plana* 3 or 4mm from the limbus. (Surgeon's view, inferotemporal sclerotomy)

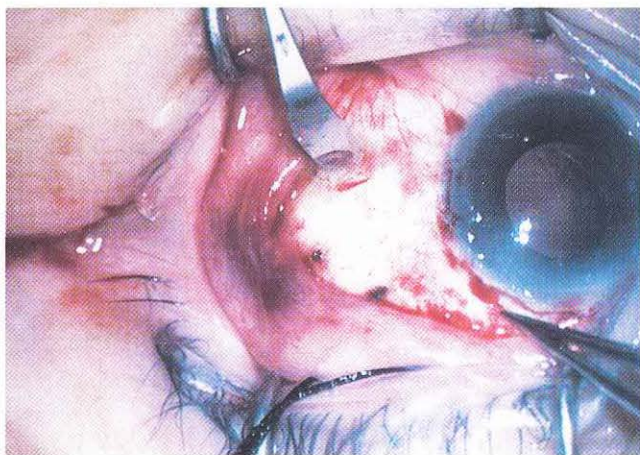


Figure 4. A partial thickness scleral incision is fashioned radial to the limbus, with the cutting edge of the crescent knife held perpendicular to the surface of globe. (Surgeon's view, inferotemporal sclerotomy)

bevel-up blade (Crescent Knife®, Alcon Laboratories Inc, Fort Worth, Tex) with its sharp, advancing edge directed radial to limbus (**Figure 4**). With the same crescent knife, a tunnel incision is then made parallel to the limbus to create a scleral flap. This tunneling dissection is carried to a point slightly anterior to the site of intended entry (**Figure 5**). With the scleral flap retracted superiorly, a 20-gauge round body hypodermic needle is used to enter the vitreous cavity perpendicular to the scleral surface 3 or 4 mm posterior to the limbus (**Figure 6**). A MVR blade is not used to avoid accidental scleral flap laceration made by the sharp MVR blade. With the openings of the superior sclerotomies orientated peripherally, instrumentation through these sclerotomies becomes very easy (**Figure 7**). The opening of the inferotemporal scleral pocket is made to face inferiorly so as to avoid the infusion tubing from getting into the way of the surgical field. The tip of the infusion cannula is then lying tangential to the limbus and away from the lens. The cannula is secured by suturing to the sclera, or taping to the drape.

Comment

A self-sealing scleral incision with a stepped wound

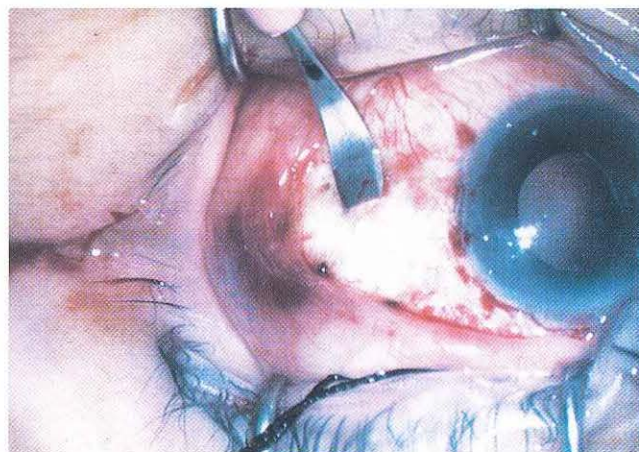


Figure 5. A scleral tunnel incision of 2mm long is made by advancing the crescent knife parallel to the limbus. (Surgeon's view, inferotemporal sclerotomy)

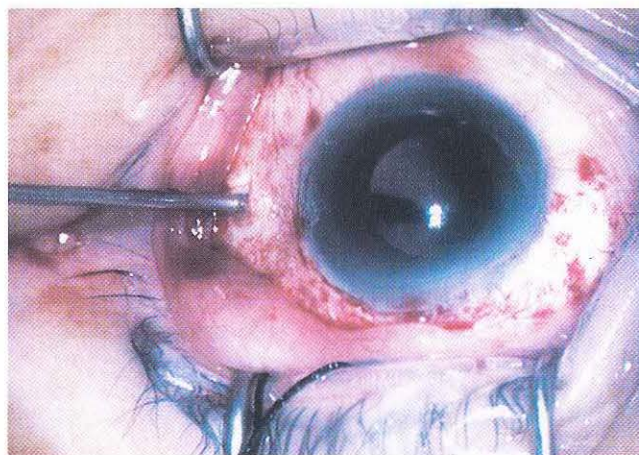


Figure 6. With the scleral flap retracted anteriorly, a 20-gauge round body hypodermic needle is used to puncture the globe at the *pars plana* 3 or 4mm posterior to the limbus. (Surgeon's view, inferotemporal sclerotomy)

construction is frequently employed by cataract surgeons during phacoemulsification cataract extraction.^{4,5} The application of this technique in preparing *pars plana* sclerotomies is useful to solve some of the intraoperative and postoperative problems commonly encountered in modern *pars plana* vitrectomy.

Herniation of retinal tissue into sclerotomy sites is a well-known complication during vitrectomy in eyes with very mobile detached retina. This happens during intraocular instrument exchange leading to leakage at the site of sclerotomy. This new type of wound construction can minimize this complication. Similarly, the chance of vitreous herniation through this type of sclerotomy may also be diminished. Intraoperative endoscopy or postoperative ultrasound biomicroscopy may be useful to address this speculation.

Another complication during vitrectomy is intraoperative bleeding. The traditional management of significant bleeding is to raise the height of the infusion bottle and to keep all intraocular instruments in the eye to allow pressure tamponade to occur. Sometimes, with the traditional wound

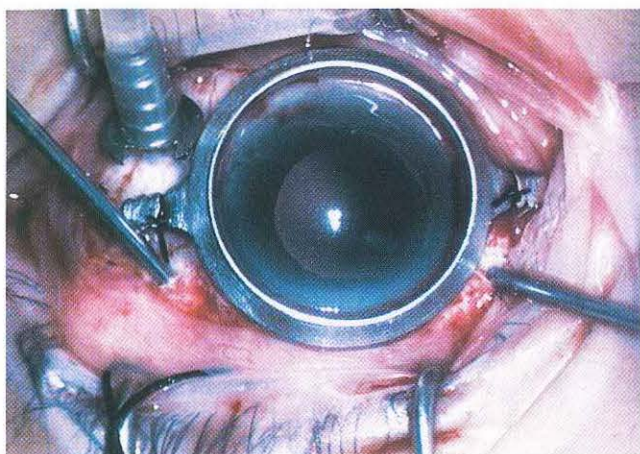


Figure 7. Instrumentation through the superior sclerotomies, which orientate peripherally (Surgeon's view)

construction of the sclerotomies, even after extended tamponade, as soon as the instruments are removed from the eye, rebleeding occurs because of the sudden decrease in intraocular pressure caused by fluid leaking through the sclerotomy wounds. This new type of sclerotomy construction can withstand high intraocular pressure during surgery. Effective pressure-tamponade in case of bleeding can still be achieved after removal of the intraocular instruments, allowing the surgeon to carry out frequent instrument exchanges if necessary. This in turn reduces surgeon's fatigue and operative time.

Postoperatively, the incidence of wound leak is reduced. Suture problems, for example, suture ends that erode through the conjunctiva and cause postoperative irritation, can be totally avoided. Conjunctival pigmentation has been associated with episcleral sutures after pars plana vitrectomy. Besides cosmetic problem, marked conjunctival melanosis with dark brown spots that required excision has been reported.⁶ This can also be eliminated by the above-mentioned techniques.

Leakage from the sclerotomy sites did not occur in the initial report of 47 primary vitrectomies using the above-mentioned

first technique.³ Subsequent studies reported a success rate of 41-78%.^{7,8} We applied the second above-mentioned modified technique on 25 consecutive vitreoretinal patients at the Prince of Wales Hospital from September to October, 1997. Twenty out of the 25 patients (80%) had all their modified sclerotomies self-sealed. Eight out of the 75 modified sutureless sclerotomies (9%) in our 25 patients required suturing at the end of the operations. It appears that the rotation of the scleral pocket does not compromise the success rate of this technique. Usually, leakages are due to defects in the scleral flap. This can be lessened by avoiding thin scleral flaps and also meticulous handling of sharp instruments.

Although not encountered in the initial reported series, there may be other potential complications with this technique. These can include the sclerotomy entry site being too far anterior or too far posterior. A posteriorly placed sclerotomy may cause a peripheral retinal tear because of vitreous traction or direct trauma to the retina. An anteriorly placed sclerotomy may lead to inadvertent lens damage and cataract formation. When the infusion cannula is not fixed, there is a possibility of slippage leading to choroidal detachment or hemorrhage. Specially designed curved self-retaining infusion cannula may further improve the safety and simplicity of these techniques. Also, in rare cases in which the sclera is thin, a stepped incision, as proposed here, may be dangerous to achieve and should be avoided.

There are reported cases of endophthalmitis after sutureless phacoemulsification cataract extraction surgery.^{9,10} Although not proven, it has been suggested that an unsutured cataract wound would allow communication with the extraocular environment and predispose to postoperative endophthalmitis. Similar arguments certainly apply to our sutureless sclerotomies. However, sclerotomies are much smaller, are positioned further posterior than in standard cataract procedures, and are usually well covered by conjunctiva after the surgery. The risk of endophthalmitis is therefore theoretically lower.

These new ways of constructing *pars plana* sclerotomies have many advantages, and we recommend them as an alternative to standard sclerotomy incisions.

References

1. Zauberman H, Hemo I. The use of a silicone strip over the sclerotomy in vitreous surgery. *Ophthalmic Surg.* 1995; 26(4): 360-1.
2. Charles S. General posterior segment techniques. In: *Vitreous Microsurgery*. 2nd ed. Baltimore, Md: Williams & Wilkins; 1987:99-100.
3. Chen JC. Sutureless pars plana vitrectomy through self-sealing sclerotomies. *Arch Ophthalmol.* 1996; 114: 1273-1275.
4. Devine TM, Banko W. Surgical procedure. In: *Phacoemulsification Surgery*. Elmsford, NY: Pergamon Press Inc; 1991:34-38.
5. Fine IH, Fichman RA, Grabow HB. *Clear Corneal Cataract Surgery and Topical Anesthesia*. Thorofare, NJ: Slack Inc; 1993.
6. Smiddy WE, Yeo JH, Michels RG, Green WR. *Conjunctival pigmentation following pars plana vitrectomy*. *Retina.* 1987; 7:38-40.
7. Milibak T, Suveges I. Complications of sutureless pars plana vitrectomy through self-sealing sclerotomies. *Arch Ophthalmol.* 1998; 116: 119.
8. Korobelnik JF, Hannouche D, Cochereau I, Hoang-Xuan T. Self-sealing sclerotomies in pars plana vitrectomy. *J Fr Ophthalmol.* 1997; 20(10): 779-784.
9. Miller KM, Glasgow BJ. Bacterial endophthalmitis following sutureless cataract surgery. *Arch Ophthalmol.* 1994; 112:301-302.
10. Stonecipher KG, Parmley VC, Jensen H, Rowsey JJ. Infectious endophthalmitis following sutureless cataract surgery. *Arch Ophthalmol.* 1991; 109: 1562-2563.