

# Etiological agents and risk factors of microbial keratitis in Hong Kong: a preliminary report on the first 50 cases

*The Hong Kong Microbial Keratitis Study Group (Prince of Wales Hospital and Hong Kong Eye Hospital)*

*Prince of Wales Hospital:* Dennis S. C. Lam,<sup>1</sup> FRCS, FRCOphth, Elizabeth T. S. Houang,<sup>2</sup> FRCPATH, FRCMBiol, Dorothy S. P. Fan,<sup>1</sup> MBChB, Alfred T. S. Leung,<sup>1</sup> FRCS, FRCOphth, Angus K. K. Wong,<sup>1</sup> FRCS, Augustine F. B. Cheng,<sup>2</sup> MD, FRCPATH  
<sup>1</sup>Department of Ophthalmology and Visual Sciences, <sup>2</sup>Department of Microbiology, the Chinese University of Hong Kong, Hong Kong.

*Hong Kong Eye Hospital:* Team A: Agnes T. Y. Tse, FRCS, FRCOphth, Wai-Kwan Wu, FRCS, FCOHK; Team B: Chung-Chai Chi, FRCS, FHKAM, Nai-Man Lam, FRCS, FHKAM, Betty T. M. Poon, FRCS, FHKAM; Team C: Yue-Kwong Au, MD, Chi-Yuen Siu, FRCS, FHKAM

## Correspondence and reprint requests:

Dennis S. C. Lam, FRCS, FRCOphth, Department of Ophthalmology and Visual Sciences, The Chinese University of Hong Kong, Prince of Wales Hospital, Shatin, N.T., Hong Kong.

## Abstract

**Aim:** The aim of the study was to determine locally the etiology and risk factors of microbial keratitis, which might be different from those reported in Western countries, because of different climatic, cultural and environmental conditions.

**Materials and methods:** We prospectively recruited all cases of presumed microbial keratitis from the Hong Kong Eye Hospital and Prince of Wales Hospital from March 1997 to September 1997. Clinical diagnosis of microbial keratitis was established when the corneal infiltration was at least 1mm in diameter. Corneal scrapings were performed and cultured in all cases. Correlation between risk factors, clinical presentations and culture results were examined.

**Results:** Fifty consecutive patients were studied. The important risk factors included contact lens wear, ocular injury, ocular surface disease and previous application of steroid. Fifty-four percent of the cases had positive

microbial cultures from corneal scrapings. The culture positive rate was significantly related to the presence of anterior chamber activity. Neither the size nor the position of infiltration was associated with a positive culture. Among patients without a history of contact lens wear, *Pseudomonas aeruginosa*, the commonest pathogen, was recovered in scrapings from nine patients and *Staphylococcus aureus* from another three patients. *Acanthamoeba* and *Pseudomonas aeruginosa* were the commonest isolates from contact lens wearers.

**Conclusion:** Contact lens wearing was the most important risk factor of microbial keratitis in Hong Kong. Particular attention should be paid to patients presenting with anterior chamber activity. The first-line antibiotic treatment should be effective against *Pseudomonas aeruginosa* and *Staphylococcus aureus*, the two commonest bacteria associated with microbial keratitis in Hong Kong.

**Key words:** Microbial keratitis, Corneal ulcer, Risk factors, Clinical presentation, Sensitivity



## Introduction

Microbial keratitis is a potentially blinding condition, which may lead to corneal perforation or even endophthalmitis. Early recognition and prompt treatment is important to prevent severe damage.<sup>1,2</sup> Contact lens wear is recognized as one of the most common risk factors for this serious condition.<sup>3-5</sup> With the growth of contact lens use since the 1980s, contact lens wear has surpassed ocular trauma as the primary predisposing factor for ulcerative keratitis in London and the United States.<sup>3,5</sup> Affected individuals are likely to be young adults. In addition, more risks have been found to be associated with the currently available extended contact lens wear.<sup>6</sup>

*Staphylococcus aureus* and *Pseudomonas aeruginosa* are the common pathogens associated with microbial keratitis. Fungi and mycobacteria have also been described.<sup>9-11</sup> Recently, attention has been drawn to the free-living protozoon, *Acanthamoeba*, which has been identified among contact lens related infections in all parts of the world.<sup>12-15</sup> In Hong Kong, the first culture proven *Acanthamoeba* keratitis was described in 1993.

According to the Hong Kong Census 1991, approximately one third of the whole population was within the age of 19 to 39 and over 70% of these were myopic.<sup>7</sup> The number of contact lens users has been estimated to be between 300,000 and 400,000 and is expected to increase further. There is, however, little information on the etiology and risk factors of ulcerative keratitis in Hong Kong or Asia. Such information is important in the devising of an optimal strategy for the management of microbial keratitis, as it is recognized that there are regional variations in the relative importance of microbial agents and risk factors.<sup>9</sup> We report here the preliminary results of a prospective study on microbial keratitis in Hong Kong.

## Materials and methods

All patients from the Hong Kong Eye Hospital and the Prince of Wales Hospital who presented with a clinical diagnosis of ulcerative keratitis were recruited. Ulcerative keratitis was defined as the presence of corneal infiltrate of more than 1mm in diameter, with or without epithelial defects.

Using preservative-free 1% amethocaine hydrochloride (Tetracaine, Chauvin Pharmaceuticals, Romford, England) eye drop for local anesthesia, corneal scrapings were performed in all cases. Inoculation of various cultural media was carried out at the time of the procedure. The cultural media were then incubated immediately and examined using routine laboratory techniques. Microscopy was performed on Gram-stained smears of the corneal sample. Blood and chocolate agar plates were incubated in 5% CO<sub>2</sub> for 48 hours and anaerobic culture in thioglycolate broth for 5 days, both at 37°C. Inoculated Sabouraud's slope for fungal culture was incubated at 30°C for 2 weeks. *Acanthamoeba* culture was also performed. The culture plates were incubated at 30°C and examined intermittently up to 4 weeks for the presence of cysts characteristic of *Acanthamoeba* species.

Antimicrobial sensitivity testing was performed with the disc diffusion method.<sup>16</sup>

## Results

Between March and September 1997, 50 consecutive patients, involving 26 right and 24 left eyes, were studied. Twenty patients were under the age of 40 and half of these were contact lens users. For patients over the age of 60 years, ocular surface disease (17.9%) and the application of steroid eye drops (21.4%) were the two commonest risk factors, followed by a recent history of ocular injury in 10 patients (20%) (Table 1).

Table 1. Risk factors of presumed microbial keratitis in 50 consecutive patients.

Risk factors	No. of patients	Percentage
Contact lens	14	28%
Injury	10	20%
Ocular surface disease	7	14%
Use of steroid	6	12%

Table 2. Clinical presentations of presumed microbial keratitis in 50 consecutive patients.

Clinical presentation	No. of patients	Percentage
Eye redness	28	56%
Blurring of vision	25	50%
Foreign body sensation	16	32%
Eye discharge	11	22%
Photophobia	7	14%
Pain	36	72%

The major presenting symptoms were red eye, blurring of vision, foreign body sensation, eye discharge and photophobia (Table 2). The size of the infiltration ranged from 1 mm to 7 mm (Mean:  $2.6 \pm 1.8$  mm) and its position was equally distributed, 34% in the axial area, 36% in the para-axial area and 30% in the periphery. The size of the infiltration was significantly associated with the duration of symptoms (Mann-Whitney U test,  $p=0.043$ ). Seventeen patients (34%) presented with anterior chamber activity and seven (14%) with hypopyon. The visual acuities at the time of presentation were poor for most patients, with 24 of them having "finger counting" or worse. Patients who had a history of contact lens wear had significantly better scores in visual acuity than those without (Mann-Whitney U test,  $p=0.041$ ).

The corneal specimens from 6 of the 14 patients (42.9%) with



**Table 3. Bacterial species isolated from 27 samples of corneal scrapings and the results of antimicrobial susceptibility testing by the disc method.**

\* T=Number of isolates tested; \*\* S=Number of isolates susceptible to the antibiotic tested.

	No. of isolates  (%)	Antibiotics									
		Chloramphenicol		Cotrimoxazole		Neomycin		Ofloxacin		Tobramycin	
		T*	S**	T	S	T	S	T	S	T	S
<b>Bacteria</b>											
<i>Pseudomonas aeruginosa</i>	9 (25.7)	9	0	0	0	9	9	8	8	8	8
Coagulase negative staphylococci	7 (20)	0	0	0	0	0	0	1	1	0	0
<i>Staphylococcus aureus</i>	3 (8.6)	3	1	1	1	3	1	3	3	3	2
<i>Streptococcus pneumoniae</i> & alpha-streptococci	3 (8.6)	2	2	2	1	1	0	1	1	1	0
Corynebacteria	2 (5.8)	0	0	0	0	0	0	1	1	1	0
<i>Klebsiella</i> & <i>Serratia</i> species	2 (5.8)	2	0	2	2	2	2	1	1	1	1
Non-lactose fermenting coliforms	2 (5.8)	4	3	4	4	3	3	3	3	1	0
<i>Nocardia</i> species	2 (5.7)										
<b>Fungal</b>											
<i>Trichosporon beigelii</i>	1 (2.9)										
<i>Asperigillus</i> species	1 (2.9)										
<i>Penicillium</i> species	1 (2.9)										
<b>Protozoa</b>											
<i>Acanthamoeba</i>	2 (5.7)										



a history of contact lens wear and 21 of the 36 patients (58.3%) without such a history yielded a positive culture result (Table 3). A negative culture result was not significantly associated with a previous history of antibiotic use, duration of symptoms, or the position of the infiltration. *Pseudomonas aeruginosa* was the commonest pathogen isolated (Figure 1). Two patients who were contact lens wearers had *Acanthamoeba* infection. Corneal specimens from 5 patients yielded more than one microbe. Three of these patients used steroid eye drops before presentation and 2 of them had *Nocardia* infection. Of the 22 patients whose specimens yielded a single organism, only 1 had a similar history. Previous use of steroid eye drop is therefore significantly associated with the presence of multiple microbes in the culture of corneal scrapings ( $X^2 = 0.013$ ). Antimicrobial susceptibility testing was carried out for the commonly used agents (Table 3). Ofloxacin appeared to be the most active antibiotic and all isolates tested were susceptible to it.

## Discussion

The successful management of microbial keratitis depends on prompt clinical diagnosis, microbiological investigation and appropriate treatment.<sup>1</sup> A clear understanding of risk factors and prevalent pathogens in the local population is important for a successful strategy of management to be devised. Our results show that, in Hong Kong, contact lens wearing was present in 28% of patients studied, the

commonest risk factor associated with microbial keratitis, particularly in patients less than 40 years of age (50%). This was also the primary predisposing factor in London and the United States.<sup>3,5</sup> In our series, both *Pseudomonas aeruginosa* and *Acanthamoeba* species are important pathogens for this group of patients. Previous application of steroid eye drops was another important risk factor, significantly associated with isolation of multiple organisms from corneal scrapings. Two of these patients suffered from nocardial infection, which has often been described in immunosuppressed conditions. These two cases together with the 3 cases of fungal infection highlight the need for laboratories to prolong incubation of culture plates and to culture for fungi routinely.

The culture positive rate in our samples was 54%, comparable to results reported in other studies.<sup>20-21</sup> It is important to use preservative-free anesthesia, as topical anesthetic agents has been shown to have antibacterial activity.<sup>21</sup> Previous application of antibiotic eye drops before presentation may also reduce the chance of a positive culture. In this series, the culture positive rate was 42.3% among patients who had previously received antibiotic treatment and 65.2% among patients who had not ( $X^2 = 0.094$ ). The pathogenic role of skin commensals, such as coagulase negative *Staphylococci* and *Propionibacteria* when isolated from corneal scrapings, is not clear.

Bennett *et al*<sup>2</sup> reported that infiltrates either  $\geq 4$ mm or centrally positioned were more likely to yield positive culture results. We were not able to demonstrate similar

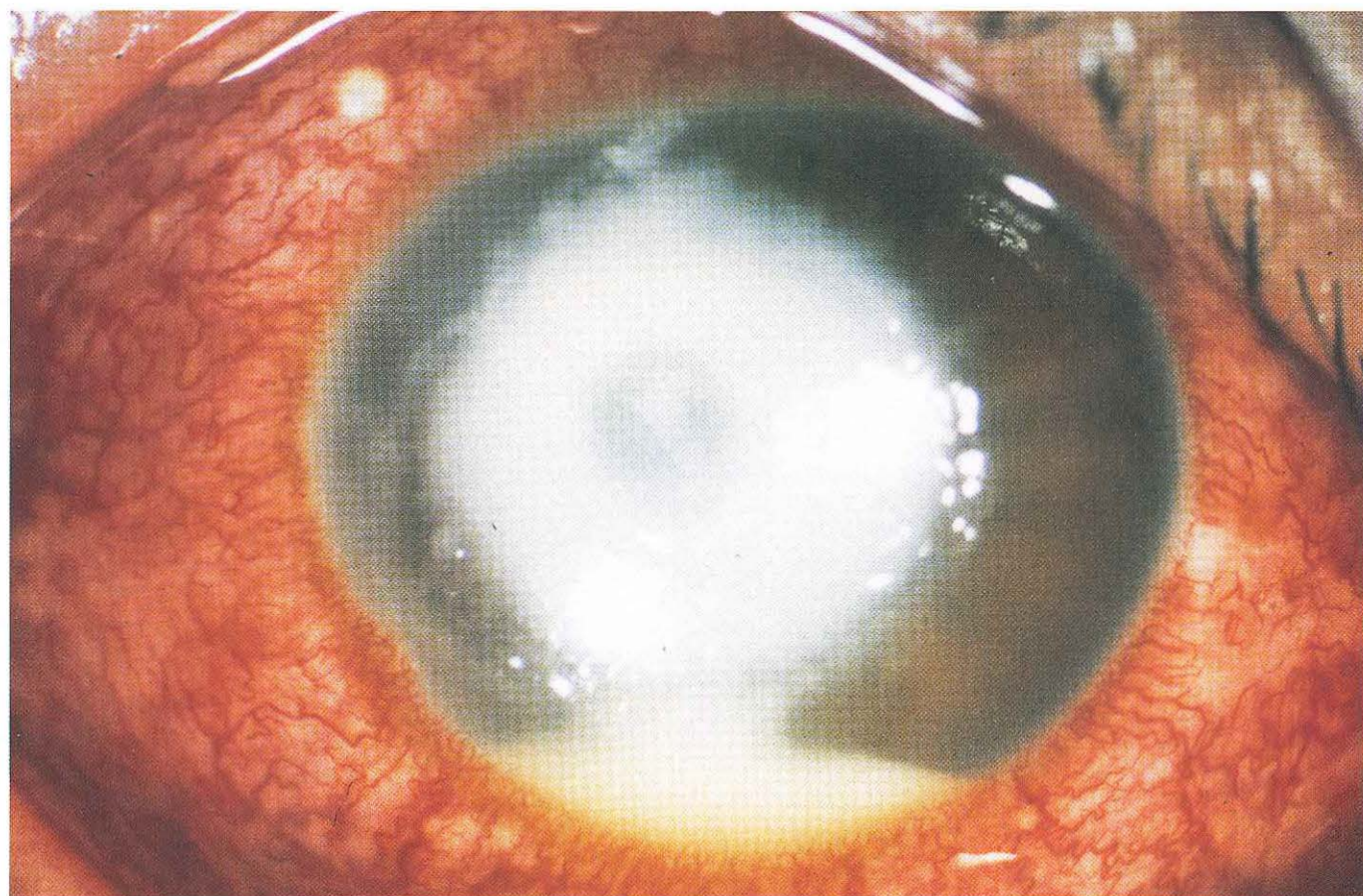


Figure 1. Slit-lamp photo shows a big central corneal ulcer and a 3 mm hypopyon.



correlation in our series. On the other hand, we also demonstrated that anterior chamber activity was positively associated with a positive culture result.<sup>2</sup>

Conventional antibiotic therapy consisted of multiple fortified medications. More recently, fluoroquinolone eye drops e.g. ofloxacin, has been introduced as a monotherapy.<sup>23-25</sup> It has broad-spectrum antibacterial activities, good ocular penetration and few adverse effects.<sup>26</sup> All the 9 *Pseudomonas* isolates obtained in our series were sensitive to it. Nevertheless, one should be mindful of its relative inactivity against *Streptococcus* species. Tobramycin was also active against all the *Pseudomonas*

isolates tested (Table 2).

In summary, the preliminary data from our study on microbial keratitis indicate that contact lens wear is the most important risk factor for the development of microbial keratitis in Hong Kong. Similar to findings in other tropical and sub-tropical regions, *Pseudomonas aeruginosa* is the commonest microbe recovered from corneal scrapings. Other important microbial agents include *Staphylococcus aureus*, *Streptococcus* spp. and fungi. As the number of contact lens users increases in Hong Kong, we should always be mindful of possible *Acanthamoeba* infection.

## References

1. Jones DB. Decision-making in the management of microbial keratitis. *Ophthalmol.* 1981;88:814-20.
2. Bennett HGB, Hay J, Kirkness CM, Seal DV, Devonshire P. Antimicrobial management of presumed microbial keratitis: guidelines for treatment of central and peripheral ulcers. *Br J Ophthalmol.* 1998;82:137-45.
3. Dart JK. Predisposing factors in microbial keratitis: the significance of contact lens wear. *Br J Ophthalmol.* 1988;72:926.
4. Gudmundsson OG, Ormerod LD, Kenyon KR, Glynn RJ, Baker AS, Haaf J, et al. Factors influencing predilection and outcome in bacterial keratitis. *Cornea.* 1989;8:115-21.
5. Erie JC, Nevitt MP, Hodge DO, Ballard DJ. Incidence of ulcerative keratitis in a defined population from 1950 through 1988. *Arch Ophthalmol.* 1993;111:1665-71.
6. Poggio EC, Glynn RJ, Schein OD, Seddon JM, Shannon MJ, Scardino VA, et al. The incidence of ulcerative keratitis among users of daily wear and extended wear soft contact lenses. *N Eng J Med.* 1989;321:779-83.
7. Goh WSH and Lam CSY. Changes in refractive trends and optical components of Hong Kong Chinese aged 19-39 years. *Ophthal Physiol Opt.* 1994;14:378-82.
8. Limberg MB. A review of bacterial keratitis and bacterial conjunctivitis. *Am J Ophthalmol.* 1991;112:2S-9S.
9. Wahl JC, Katz HR, Abrams DA. Infectious keratitis in Baltimore. *Ann Ophthalmol.* 1991;23:234-7.
10. Schein OD, Ormerod LD, Barraquer E, Alfonso E, Egan KM, Paton BG, et al. Microbiology of contact lens-related keratitis. *Cornea.* 1989;8:281-5.
11. Ficker LA, Kirkness CM, Seal DV, McCartney ACE. Microbial keratitis-the false negative. *Eye.* 1991;5:549-59.
12. Seal DV. *Acanthamoeba* keratitis. *Br M J.* 1994;308:1019.
13. Kirkness CM, Hay J, Seal DV, Aitken D. *Acanthamoeba* keratitis. *Ophthalmol. Clin North Am.* 1994;7:605.
14. Kamel AG, Norazah A. First case of *Acanthamoeba* in Malaysia. *Trans Roy Soc Trop Med Hyg.* 1995;89:652.
15. Seal DV, Hay J, Kirkness CM. *Acanthamoeba* keratitis and contact lens wear: the need for a global strategy for prevention of corneal infection. *Community Eye Health.* 1995;8(15):4-6.
16. NCCLS. Performance Standards for Antimicrobial Disk Susceptibility Tests - Sixth Edition; Approved standard. NCCLS document M2-A2. (ISBN-1-56238-308-6).
17. Asbell P, Stenson S. Ulcerative keratitis survey of 30 years' laboratory experience. *Arch Ophthalmol.* 1982;100:77-80.
18. Neumann M, Sjostrand J. Central microbial keratitis in a Swedish city population a three-year prospective study in Gothenburg. *Acta Ophthalmol.* 1992;70:160-4.
19. Allan BDS, Dart JKG. Strategies for the management of microbial keratitis. *Br J Ophthalmol.* 1995;79:777-86.
20. Levey SB, Katz HR, Abrams DA, Hirschbein MJ, Marsh MJ. The role of cultures in the management of ulcerative keratitis. *Cornea.* 1997;16(4):383-6.
21. Wang AG, Wu CC, Liu JH. Bacterial corneal ulcer: A multivariate study. *Ophthalmologica.* 1998;212:126-32.
22. Mullin GS, Rubinfeld RS. The antibacterial activity of topical anesthetics. *Cornea.* 1997;16(6):662-5.
23. Parks DJ, Abrams DA, Sarfarazi F, Katz HR. Comparison of topical ciprofloxacin to conventional antibiotic therapy in the treatment of ulcerative keratitis. *Am J Ophthalmol.* 1993;115:471-7.
24. Donnenfeld ED, Schrier A, Perry HD, Aulicino T, Gombert ME, Snyder R, et al. Penetration of topically applied ciprofloxacin, norfloxacin, and ofloxacin into the aqueous humor. *Ophthalmology.* 1994;101:902-5.
25. Bower KS, Kowalski R, Gordon YJ. Fluoroquinolones in the treatment of bacterial keratitis. *Am J Ophthalmol.* 1996;121:712-5.
26. Neu HC. Microbiologic aspects of fluoroquinolones. *Am J Ophthalmol.* 1991;112:15S-24S.