

Periphery to center dissection for stage V retinopathy of prematurity aided by temporary iris retractors — a pilot study

Lingam Gopal^{1,2}, MS, Tarun Sharma¹, MS.

1. Vision Research Foundation, Madras, India 2. Prince of Wales Hospital, the Chinese University of Hong Kong, Hong Kong
Presented at the International Conference on Retinopathy of Prematurity, Chicago, 1996

Correspondence and reprint requests:

Lingam Gopal at Sankara Nethralaya, Vision Research Foundation, 18 College Road, Madras, 600 006, India

Abstract

Aim: To discuss the results of a pilot study involving the management of stage V retinopathy of prematurity using the technique of 'periphery to center enblock dissection,' aided by temporary iris retractors and bimanual surgery.

Materials and methods: Six eyes of 5 patients with stage V retinopathy of prematurity underwent closed lensectomy and vitrectomy procedures. Temporary iris retractors were used to permit exposure of the periphery. Bimanual dissection of the fibrovascular tissue was done from the periphery to center under viscoelastic substances.

Results: Tissue dissection was very satisfactory with this technique. At last follow up, 2 eyes had total retinal reattachment, 2 eyes had posterior polar reattachment and 2 eyes had persistent total retinal detachment.

Conclusions: 'Periphery to center enblock dissection' is possible in Stage V Retinopathy of prematurity by closed route using bimanual surgery and aided by temporary iris retractors. This technique enables removal of the fibrovascular tissue very satisfactorily.

Introduction

Retinopathy of prematurity (ROP) is a potentially blinding disorder affecting very low birth weight infants. The disease was first identified by Terry in 1942 as a white retrolental glial mass, labelled as retrolental fibroplasia.¹ With routine use of the indirect ophthalmoscope, the early stages of the disease have come to be recognized. The international classification of retinopathy of prematurity (ICROP)² has contributed immensely in the staging of the disease.

At the present time, due to the improved neonatal care, it is not surprising to see even babies with 500 grams birth weight surviving. Along with this improved survival of very low birth weight infants, the incidence of ROP has also increased dramatically.³ Despite the routine screening of all infants at risk and prompt treatment of stage 3 + disease, some infants progress to stage V ROP. In the developing world, the awareness of retinopathy of prematurity is not well established among ophthalmologists and neonatologists.⁴ Hence it is not uncommon to see infants presenting to the ophthalmologist with stage V ROP for the first time.

The management of stage V ROP has been far from satisfactory. There have been two broad approaches to the management of this disease; the open sky route⁵ and the closed route.⁶ The supposed advantage of the closed route was the greater familiarity of this approach to most vitreoretinal surgeons. The open sky route claims to give better access to the periphery.

In this article we share our preliminary experience with the use of a technique that gives access to the periphery through the closed route.

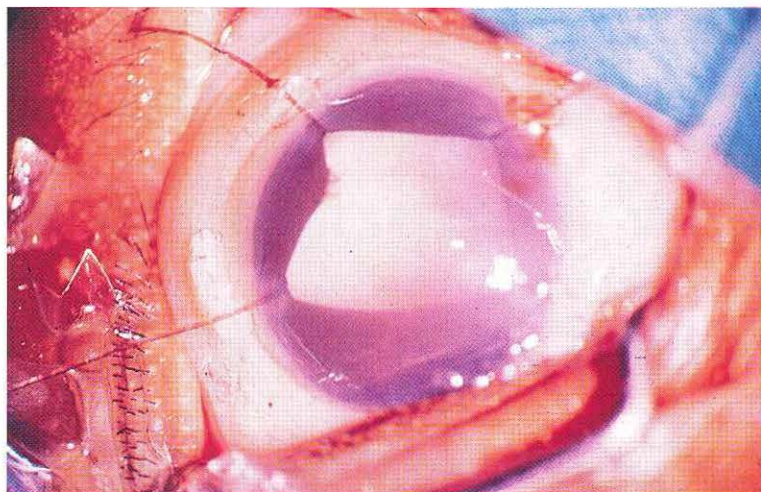


Figure 1. Intraoperative photograph showing placement of 4 temporary iris retractors (surgeon's view).

Material and methods

This is a retrospective analysis of 6 eyes of 5 patients with stage V ROP that were operated between March and September of 1996. All cases presented with stage V ROP to us and had not received any treatment in the past. There were 4 males and 1 female. The average age at presentation was 6.5 months (range 4.5 to 9 months). The mean birth weight was 1175 grams (range 900 to 1500 grams). The mean gestation age was 27.25 weeks (range 26 to 29 weeks). The preoperative work up included ultrasonography to grossly elucidate the anatomy of the retinal detachment. Five eyes had narrow-narrow configuration of the funnel, while 1 eye had open-narrow configuration.

Surgical procedure

The surgery was done under general anaesthesia with endotracheal intubation. The conjunctiva was incised at the limbus in an 'L' shaped fashion at 2 and 10 o'clock meridians. The limbus was cleaned and any troublesome bleeders were cauterized. Four temporary iris retractors (Greishaber, Switzerland) were applied at 10.15, 2.15, 4.30 and 7.30 o'clock meridians. The incisions to introduce the retractors were placed close to the limbus. Any posterior synechiae could be broken with the traction caused by the retractors. The pupil was thus stretched into a square shape (Figure 1). Two sclerotomies were made with MVR blade at 10 and 2 o'clock meridians approximately 0.5 mm from the limbus. The sclerotomies sometimes went through the iris route and sometimes behind the iris plane. When it went through the iris route, very often the uveal tissue prolapsed through the sclerotomy and needed a sacrifice of the iris in those meridians. Tracks were made into the lens through both the meridians with the MVR blade. A 30° bent infusion cannula was inserted into the lens through one sclerotomy and the cutter was introduced through the other. Lensectomy was done. The posterior capsule remained adherent to the fibrovascular tissue. The same was either peeled off using a forceps or was removed with the fibrovascular tissue during the dissection. Healon was injected to fill the eye. Bimanual dissection was done using the modified de Juan's pic forceps (Greishaber, Switzerland) and curved scissors (DORC, Holland). The fibrovascular tissue was tented up in the center and incised with the scissors. The incision was carried preferably up to the retinal surface and extended radially towards the meridian of the

two sclerotomies. This manoeuvre resulted in dividing the retrolental tissue into two sections resembling a pie chart, with the smaller fragment extending from the 10 to 2 o'clock meridians.

The next step was to dissect all-round the tissue from the ciliary body area using the anterior limits of the radial cuts as initiating points. This manoeuvre was made possible by alternating sharp dissection and cutting with the scissors while lifting the tissue with the forceps. Exposure of the periphery was adequate with the help of the iris retractors aided by gentle scleral depression using a slender muscle hook. The iris in between the iris retractors tended sometimes to obscure the visualization of the periphery. In such a situation the iris retractors were removed from a quadrant in which the periphery had already been dissected and placed in a meridian in which better exposure was needed. By placing the iris retractors in meridians where required, 360° dissection of the periphery was possible. Once the tissue was freed from its attachment to the periphery, dissection towards the opening of the funnel was relatively easy. The tissue thus dissected up to the anterior opening of the funnel was dissected down into the funnel using the curved scissors with its blades placed vertically parallel to the walls of the funnel. By this technique, very often one was able to dissect the whole tissue *en bloc*. However, in some cases the dissected tissue came in the way of proper visualization of the posterior pole and hence was trimmed at intervals with the cutter to enable further dissection into the funnel. Each time the vitreous cutter was needed to be used, the healon was exchanged with BSS and the 30° bent cannula was used to provide infusion. Minimal bleeding stopped very often by itself and the clot could be removed with the cutter. Persistent ooze was stopped by using underwater diathermy. Two cases had very small retinal dialysis recognized only by the occurrence of stream of subretinal fluid into the vitreous cavity. The dialysis itself was not directly visualized. No treatment was directed to the dialysis.

Once the dissection was completed, the sclerotomies were temporarily closed with 7-0 vicryl suture by placing slip knots while the eye was still filled with healon. This avoided collapse of the eye during suture placement. The temporary iris retractors were then removed. At this stage, BSS was reinfused with a 30 degree bent cannula and the healon was irrigated out. While the infusion was held still in position, the

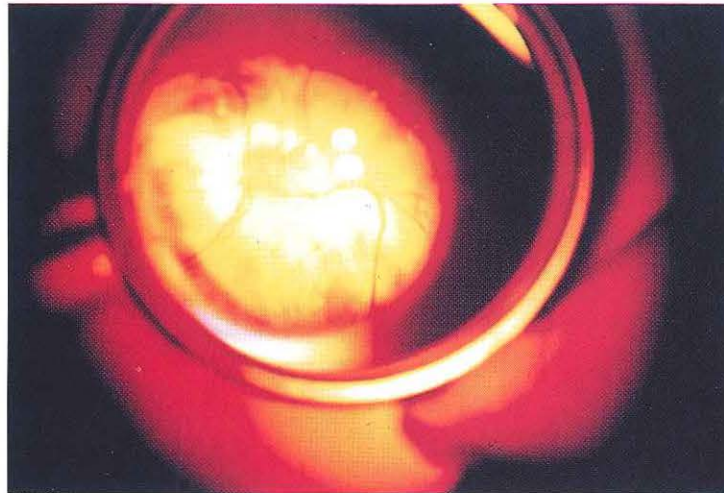

Figure 2. Four weeks postoperative photograph showing attached retina in the posterior pole (indirect ophthalmoscopic view).

opposite sclerotomy was pulled close by the assistant, using the sutures that were already in place. Similarly the infusion cannula was withdrawn while the preplaced knot was pulled tight by the assistant. Permanent knots were then placed. This manoeuvre helped in avoiding globe collapse. The conjunctiva was closed with a 7-0 vicryl suture. No attempt was made to drain the subretinal fluid and no peripheral buckle was placed. No air was injected in to the eye. Postoperatively topical steroid was used every hour for 3-4 days and then tapered. A mild mydriatic was also used. Four weeks postoperatively examination was done under general anaesthesia to evaluate the retina as well as the intraocular pressure.

Results

The follow-up ranged from 2 to 6 months with a mean of 2.75 months. There was significant inflammatory reaction on the first postoperative day in all the cases which rapidly cleared with intensive topical steroid medication. The view of the retina was restored usually by the third postoperative day. At last follow-up, the retina was totally attached in 2 eyes; attached with dry fold in 1 eye and attached only in the posterior pole in 1 eye. Figure 2 shows the fundus picture of an eye with attached retina (Indirect ophthalmoscopic view). There was persistent total retinal detachment in 2 eyes. Considering the fact that in many cases of ROP the posterior polar attachment is considered anatomical success, the overall success rate at least in the short term is 66.6 %. Among the two cases that had small retinal dialysis, one had total retinal reattachment while the other had total recurrent retinal detachment. The iris was found adherent to the peripheral retina due to recurrent proliferation in the two eyes with total recurrent retinal detachment.

Discussion

Retinopathy of prematurity affects many low birth weight infants but fortunately only a small percentage progress to a stage where vision is threatened. However with the ability of the neonatologists to save these very low birth weight infants, the problem in terms of actual numbers is significant. The cryo ROP trial⁷ has demonstrated the efficacy of cryo therapy in inducing regression of the disease and reducing the risk of unfavourable outcome by 50%. In the less developed coun-

tries, the neonatologists and ophthalmologists have still not come to grips with the reality that ROP is an important disorder and that its frequency is on the increase. It is unfortunate that routine screening of infants at risk is not done in many centers, leading to the early stages of the disease going unrecognized. Most stage V ROP cases that presented to us were identified at the stage of leukocoria.

Surgical management of stage V ROP is done using two broad approaches: the closed or the open sky approach. Advocates of the closed route cite its advantages as (a) greater familiarity with the approach, (b) better maintenance of intraocular pressure (IOP) during surgery, (c) minimal tissue distortion and (d) optimal posterior pole visualization. Open sky vitrectomy on the other hand, gives better access to the periphery, but involves additional surgery in the form of corneal transplant and there is difficulty in achieving hemostasis since the IOP cannot be raised.

The pathoanatomy of stage V ROP is widely variable, but basically involves tractional retinal detachment that has a trough in the periphery and a funnel in the centre. The trough is of variable width and depth in different meridians. The funnel can be narrow or open anteriorly and posteriorly. Pars plana is absent and the retina is pulled forward as far as the ciliary processes. The fibrovascular tissue fills the space between the retina and lens as well as the funnel formed by the retinal detachment.

Considering the above pathoanatomy, it is obvious that the surgical approach to stage V ROP differs grossly from that of adult retinal detachments. An infusion cannula cannot be placed with safety because of near certainty of causing retinal dialysis. Hence a two-port procedure is usually adopted. Although infusion into anterior chamber has been tried to permit bimanual surgery, this induces corneal distortion and corneal edema. In the closed route described by Trese,³ the posterior pole is cleared first followed by delamination of the tissue from the center to the periphery. Hirose et al⁸ described the open sky route, wherein, following removal of the corneal button and the lens, the fibrovascular tissue was dissected from the periphery to the center by a two handed technique. Periphery to center dissection is associated with greater possibility of *en bloc* dissection of all the tissue and better relief of all traction. Center to periphery dissection is usually

piecemeal and could be associated with leaving behind unrelieved traction. In this surgical technique described by us, we tried to combine the advantages of open sky and closed routes of vitrectomy. Basically the tissue was dissected from the periphery to the center in a modified *en bloc* fashion.

The use of disposable iris retractors facilitated good peripheral exposure and aided by gentle scleral depression allowed good peripheral dissection. By initiating the dissection in the periphery and working our way posteriorly, the trough in the periphery was well exposed. We faced difficulty in initiating the dissection directly in the periphery. This was overcome by making two radial cuts from the center all the way to the periphery and using these as starting points for circumferential dissection. We also faced manoeuvring problems in continuing the circumferential dissection across the sclerotomy meridians, since one of the two instruments involved in the bimanual dissection had to be withdrawn nearly totally. This problem was overcome by making the initial two radial cuts in the meridians of the sclerotomies, so that there was no need to cross over the sclerotomy meridians during circumferential peripheral dissection. Effectively, the periphery was dissected in two segments that were separated by the two radial cuts.

Once a 360° peripheral cut was made at the anterior limit of the fibrovascular tissue, dissecting the flap posteriorly became easier. Bimanual surgery was performed using the pic forceps and curved vitreous scissors. This was made possible by the use of viscoelastic substance in the eye that prevented the globe from collapsing. Intermittent topping of the viscoelastic substance was done depending upon the need. We did not feel the need to keep an indwelling tubing to

facilitate healon injection without withdrawing other instruments from the eye. Visualization of the posterior pole was adequate and did not need the use of illuminated instruments.

We feel that dissection and removal of preferably all the tissue releases all the retina that is caught up in the folds and creates the best environment for total retinal reattachment. In many cases, it is not possible to clear all the tissue in the periphery. However we feel that if this rim of tissue does not hold any trough in it, it may not be significant. Small retinal dialysis can occur despite the best precautions taken to avoid undue exertion of traction on the peripheral retina. These were mostly recognized by the occurrence of streams of subretinal fluid into the vitreous cavity rather than by their direct visualization. The small dialysis did not appear to have directly influenced the outcome of the surgery in this series, despite the lack of any treatment directed to the same. Of the 2 eyes with intraoperatively noted small retinal dialysis, one had total retinal reattachment and the other had total recurrent retinal detachment. The inflammatory reaction and some degree of recurrent fibrosis that often take place after the surgery can probably seal these dialysis. A significantly large visible dialysis would obviously be a disaster to the eye. We found retinal reattachment would be obvious by 3-4 weeks, if it did occur. If by this stage, the retina did not attach itself, further improvement was unlikely.

In conclusion, the technique described above using iris retractors and bimanual surgery under viscoelastics, appears to permit near total removal of all the fibrovascular tissue from periphery to center by a closed route. The long-term results of this technique need to be studied in a much larger series. ●

References

1. Terry TL. Extreme prematurity and fibroblastic over growth of persistent vascular sheath behind each crystalline lens .I. Preliminary report. *Am J Ophthalmol* 1942;25: 203.
2. The Committee for the Classification of Retinopathy of Prematurity. An international classification of retinopathy of prematurity. *Arch Ophthalmol* 1984;102:1130-4.
3. Trese MT. Retinopathy of prematurity. in *Retina*. Ryan SJ (ed). C V Mosby Co, St Louis 1994: 2449-62.
4. Gopal L, Sharma T, Ramachandran S, Shanmugasundaram RR, Asha V. Retinopathy of prematurity - a study. *Ind J Ophthalmol* 1995;43:59-65.
5. Tasman W, Borrone RN, Bolling J. Open sky vitrectomy for total retinal detachment in retinopathy of prematurity. *Ophthalmology* 1987;94:449-52.
6. Trese MT. Visual results and prognosticating factors for vision following surgery for Stage V retinopathy of prematurity. *Ophthalmology* 1980;93: 574-9.
7. Cryo therapy for retinopathy of prematurity co-operative group: Multi centric randomised clinical trial of cryo therapy of retinopathy of prematurity- Preliminary results. *Arch Ophthalmol* 1988;106:471-91.
8. Hirose T, Schepens CL, Katsumi O, et al. Open sky vitrectomy for severe retinal detachment caused by advanced retinopathy of prematurity. in: *Retinopathy of prematurity*. Flynn JT, Tasman W (eds). Springer Verlag, New York 1992:95-114.