

# Secondary glaucoma due to silicone oil trapped in the posterior chamber

Lingam Gopal, MD, Lingam Vijaya, MD

Vitreoretinal Service, Sankara Nethralaya, Vision Research Foundation, 18 College Road, Chennai 600 006, India.

## Correspondence and reprint requests:

Lingam Gopal, Sankara Nethralaya, Vision Research Foundation, 18 College Road, Chennai 600 006, India

## Acknowledgment

Supported by Vision Research Foundation, 18 College Road, Chennai 600 006, India. The author has no proprietary interest in this study.

## Abstract

**Aim:** To describe an unusual complication of silicone oil usage.

**Materials and methods:** A 58-year-old myopic patient with pseudophakia and recurrent retinal detachment underwent vitrectomy with silicone oil tamponade. Three weeks after surgery, he developed secondary glaucoma with oil filling the anterior chamber. YAG iridotomy resulted in the oil moving between the iris and the intraocular lens leading to a flat anterior chamber. YAG capsulotomy did not cause the oil to enter the vitreous cavity. Emergency oil removal was performed.

**Results:** Removal of oil from the posterior chamber and vitreous cavity resulted in control of intraocular pressure.

**Conclusion:** Subclinical zonular dehiscence could cause oil to enter the anterior chamber in pseudophakic eyes. Creation of a 6 o'clock iridotomy can move the oil behind the iris but not into the vitreous cavity.

**Key words:** Silicone oil, Secondary glaucoma, Retinal detachment

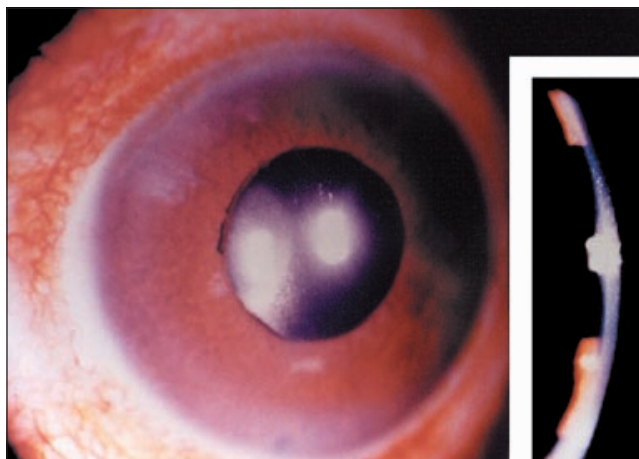
## Case report

A 58-year-old male had a history of myopia in both eyes. Successful scleral buckle surgery was performed in his right

eye 15 years previously. He underwent an uneventful phacoemulsification with intraocular lens (IOL) implantation in the left eye 1 year previously, and a scleral buckle for rhegmatogenous retinal detachment in the same eye 3 months previously. He developed recurrent retinal detachment in the left eye due to severe proliferative vitreoretinopathy for which he underwent vitrectomy, membrane stripping, and silicone oil tamponade. There were no complications at the time of the operation. On the first postoperative day, the anterior chamber (AC) had a few oil bubbles, intraocular pressure (IOP) was normal, and the retina was attached. The patient returned on an emergency basis 23 days after surgery with an acute rise in IOP. The IOP was 50 mm Hg and the AC was deep and filled with silicone oil. Glittering reflex was seen on the iris surface due to oil in the AC. YAG iridotomy was performed at the 6 o'clock position, resulting in movement of oil into the posterior chamber. The AC became flat and the IOL capsule diaphragm moved far back (**Figure 1**). With the intention of creating a path into the vitreous cavity, a capsular opening was created by YAG laser just outside the inferior border of the IOL with no success. The same could not be done at the 6 o'clock iridotomy site due to difficult visualization of the capsule through the iridotomy. Therefore, emergency removal of silicone oil from the vitreous cavity and posterior chamber was performed along with AC reformation. Postoperatively, the IOP normalized without medication and the retina remained attached.

## Discussion

This case represents a unique complication of silicone oil usage. Ando first described the use of inferior iridectomy for aphakic eyes filled with silicone oil.<sup>1</sup> Prior to the use



**Figure 1.** External photograph showing a flat anterior chamber and pseudophakos. Inset shows slit lamp photo. Note 6 o'clock iridotomy.

of inferior iridectomy, secondary glaucoma was common due to pupillary block. Inferior iridectomy allows fluid that has collected below the lighter silicone oil access to the anterior chamber, preventing pupillary block. Although migration of oil into the AC is described in pseudophakic eyes,<sup>2</sup> routine inferior iridectomy is not recommended for these patients since they are expected to present an intact diaphragm, keeping the oil in the vitreous cavity. If, however, there is a central YAG capsulotomy or evidence of zonular dehiscence (as evidenced by entry of air into the AC during fluid-air exchange), there is a need for inferior iridectomy, since the oil can gain access to the AC, resulting in glaucoma. In this situation, an opening would also need to be made in the capsule behind the iridectomy site. Subclinical zonular dehiscence is known to occur during vitrectomy.<sup>3</sup> The

incidence is expected to be higher in patients in whom vigorous scleral depression is utilized.

In our patient, there was no clinical indication of zonular dehiscence during surgery, so inferior iridectomy and capsulotomy was not performed. The presence of a few oil bubbles in the AC in the immediate postoperative period indicated that zonular dehiscence was indeed present.

However, after several days, the oil filled the AC leading to severe glaucoma. Logically, creation of an inferior iridectomy should have led to reversal of the passage of oil into the vitreous cavity through the same zonular dehiscence. YAG laser has been used to reopen blocked inferior iridectomies successfully.<sup>4</sup> The behavior of the eye in the present case can probably be explained as follows. Once the inferior iridectomy was performed, the aqueous could find its way into the anterior chamber and could push back the oil behind the iris. However, the oil could not return to the vitreous cavity through the zonular dehiscence. This resulted in the oil blocking the inferior iridectomy leading to the flattening of the AC and oil entrapment in the posterior chamber. Oil is known to block an otherwise patent peripheral iridectomy. YAG capsulotomy was done inferiorly just outside the intraocular lens but not corresponding to the site of inferior iridectomy. This did not help to correct the situation and emergency oil removal was required. The possible explanation for the failure of the YAG capsulotomy to provide a passage backwards for the oil is the lack of alignment of the capsulotomy with the iridectomy, although both were inferiorly located. We could not perform capsulotomy through the iridectomy due to visualization difficulties.

## References

1. Ando F. Intraocular hypertension resulting from pupillary block by silicone oil. *Am J Ophthalmol* 1985;99:87-88.
2. Leaver PK. Complications of silicone oil. In Ryan SJ (ed). *Retina*. Vol. 3. St Louis: Mosby Yearbook Co., 1994:2167.
3. Zivojnovic R. *Silicone oil in vitreo retinal surgery*. Dordrecht: Martinus Nijhoff, Dr W Junk Publishers, 1987:132.
4. Abrams GW, Azen SP, Barr CC, et al. The incidence of corneal abnormalities in the silicone study. *Silicone study report 7. Arch Ophthalmol* 1995;113:764-769.