

Aesthetic eyelid surgery in Asians: an East-West view

William P. D. Chen, MD

Department of Ophthalmology, Jules Stein Eye Institute, University of California School of Medicine, Los Angeles, USA, and Department of Ophthalmology, Irvine College of Medicine, Irvine, California, USA.

Correspondence and reprint requests:

William P. D. Chen, 2865 Atlantic Avenue, Suite 220, Long Beach, California 90806, USA.

Abstract

A synopsis of major misconceptions, myths, and pitfalls regarding aesthetic blepharoplasty and eyelid crease procedures in Asians is presented. Some of the parameters contributing to sub-optimal results are outlined. It is hoped that this will help illuminate some of the hazards that practitioners of this form of aesthetic eyelid surgery may encounter.

Key words: Aesthetic eyelid surgery, Asian blepharoplasty, Double eyelid surgery, Eyelid crease

Introduction

There are a great many myths and misconceptions about eyelid surgery for Asians. The conventional view that Asian eyelid surgery became popular only after the Second World War with the industrialization and westernization of Asia is inaccurate. There has always been a demand for this type of cosmetic surgery in Asia and the first 20 descriptions of the double eyelid crease procedure were published in the Japanese medical literature between 1896 and 1940. In the western hemisphere, during the past 30 years, there has been a rise in demand as more Asians settle abroad.

The demographics of Asians seeking eyelid crease procedures are of a relatively young, affluent, and educated group. However, although these patients are educated, their understanding of what they want and of what can be achieved may not be synonymous. Patients may not be aware of the normal wound healing processes and the operating surgeon may not be fully informed of what is involved in this specialized aspect of aesthetic eyelid surgery. Almost all the complications and sub-optimal results may be related to a lack of communication between

the patient and surgeon, and the inability of the surgeon to observe certain fundamental concepts and thereby avoid pitfalls.

In recent years, studies published in the ophthalmic and plastic surgery literature have compared the anatomical differences of Asians without a lid crease with Caucasians with a lid crease. We are, however, still unclear about the anatomical details of Asian eyelids with a lid crease, and the anatomy of Caucasian lids without a crease. 'Asian' eyelids, as defined by this author, are associated with Asians with 'Han' features; namely Chinese, Japanese, Koreans, and certain ethnic groups in the countries of Southeast Asia, including Vietnam, Cambodia, Malaysia, and Singapore. This definition excludes Indians from the Asian sub-continent of India and Russians, as their anatomy is similar to that of Caucasians. It has been estimated that of the 56 officially recognized ethnic groups in China today, just one — the Han — makes up the bulk of the population, comprising about 1.1 billion people. The other 55 ethnic minority groups encompass approximately 100 million people throughout China. The term 'Asian' is preferable to 'Oriental', as the latter is a non-specific, racially stereotypic, and ethnically biased term.

Misconceptions and myths

Among the many misconceptions and myths is the concept that most Asians do not have an upper eyelid crease. This could be due to the fact that usually only those patients who do not have a crease would consult surgical practitioners. The lid crease occurs in varying incidence among different ethnic subsets of Asians,¹ whether they are Chinese, Japanese, or Korean. It even shows provincial and geographical variance; for example, northern *versus* southern Chinese; Japanese from Hokkaido *versus* those from the more southern province of Kyushu. Overall, among Chinese, the average incidence of an eyelid crease is 50%. This means

that one in two are likely to have an upper eyelid crease, a ratio that holds true among parents and siblings (for example, two of four brothers and sisters or one of the two parents will have an upper eyelid crease).

The crease occurs in direct correlation to the height (vertical size) of the superior tarsal plate (as measured over the central portion above the pupillary aperture). Asians are generally smaller in physical stature than Caucasians. Their tarsal plate height averages 6.5 to 8.0 mm and the crease, when present, is usually no more than this distance from the ciliary margin (eyelid margin). The crease is no less prominent in Asians than in non-Asian groups with respect to the depth of inward folding of the crease line. One of the reasons that the lateral canthus appears to be more upwardly slanting may be the presence of a fold of skin over the crease, partially blocking the upper medial half of the palpebral fissure.

The term ‘westernizing blepharoplasty’ is still used to describe the crease procedure that Asians elect to undergo.² This could be complicating and misleading to the patient and physician alike, as Asians do not necessarily want to have the height and crease configuration of a Caucasian or ‘western’ eye. Invariably, they want to look like other Asians who have an eyelid crease — a very different crease to that of a Caucasian. If the surgeon has a less than perfect concept of this Asian crease, difficulty is likely to be encountered.

There has been much debate and conflicting findings regarding the fat compartments and location of the fat pads in the upper lid of Asians. Various theories have been invoked to explain the presence of fat pads in the pretarsal region of the upper lid, from postulating a lower point of fusion of the orbital septum to having a ‘leaky septum’ allowing isolated fat pads to migrate downwards even though the orbital septum-levator fusion point is above the superior tarsal border. Uchida was the first author to describe the findings of pretarsal fat in some Japanese patients.³ My view is that the pretarsal fat relates to ‘pre-septal’ or sub-muscular (sub-orbicularis) fat which is an extension of the sub-brow fat found in the pretarsal region of the tarsus (pre-septal is a poor term for this location as there may not be any septum here). Asians may have pretarsal fat anterior and inferior to the point of fusion of the levator aponeurosis and orbital septum — the pretarsal fat does not arise purely from the fact that pre-aponeurotic fat pads have gravitated inferiorly to the pretarsal area as a result of a lowered point of fusion of the septum-levator or from a ‘loose’ or ‘leaky’ septum. It is different in texture and configuration, more micro-lobular and amorphous than the pre-aponeurotic fat that is seen above the septum-levator point of fusion. These findings are not unique to Asians and may be seen in Caucasians as well. **Figure 1** shows the presence of pretarsal fat anterior to the orbital septum, overlying the anterior surface of the upper tarsus, and is not a part of the pre-aponeurotic fat pads, which are posterior to the orbital septum.

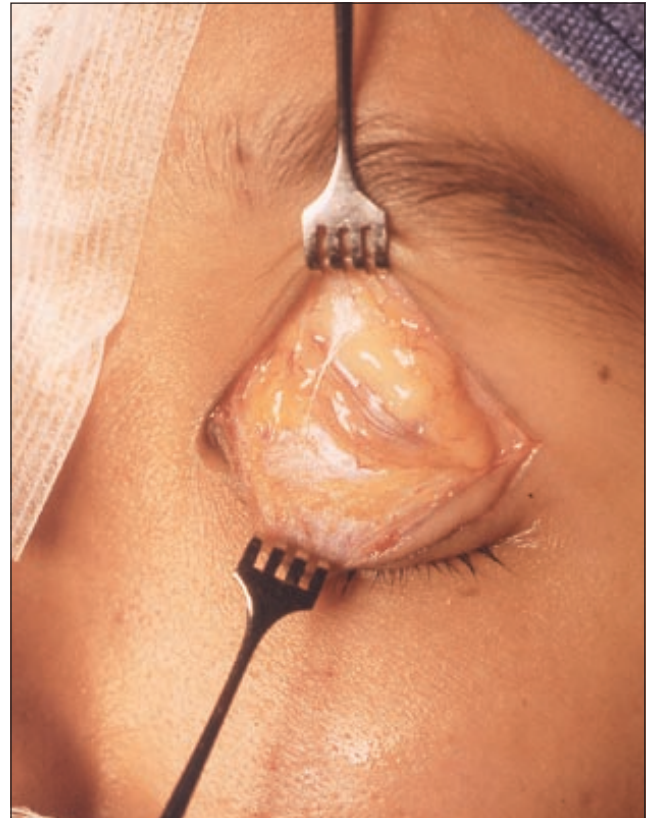

Figure 1. The left upper eyelid incision shows three zones of fat pads in this Asian patient: the pure yellowish pretarsal fat pads located in the anterior surface of the upper tarsus, anterior to the opened orbital septum above; the orange-pinkish vascularized pre-aponeurotic (post-septal) fat pads with capillaries running horizontally through; and the sub-brow fat pads above which appear pale yellowish, and are located anterior to the opened orbital septum.

Further confusion in terminology undermines the communication between patients and physicians. The terms ‘outer double eyelid’ and ‘inner double eyelid’ refer not to the higher crease found in Caucasians (**Figure 2**) versus the lower crease seen in those Asians who possess a crease, but to the relative configuration (shape) of the crease as seen in an Asian. The term ‘outer double eyelid’ merely refers to a crease that does not converge to the medial canthus — ‘parallel’ is a more appropriate anatomical term (**Figure 3**).



Figure 2. A typical semilunar Caucasian crease. The crease is high by the Asian norm and appears more separated from the lid margin over the central one-third of the eyelid.

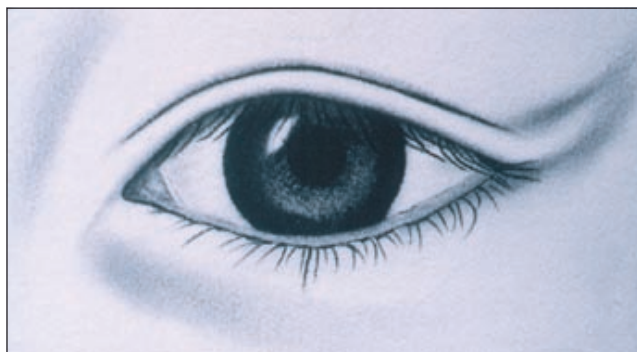

Figure 3. Schematic drawing of a parallel crease configuration. The crease runs equidistant from the lid margin, from the medial to the lateral canthus.

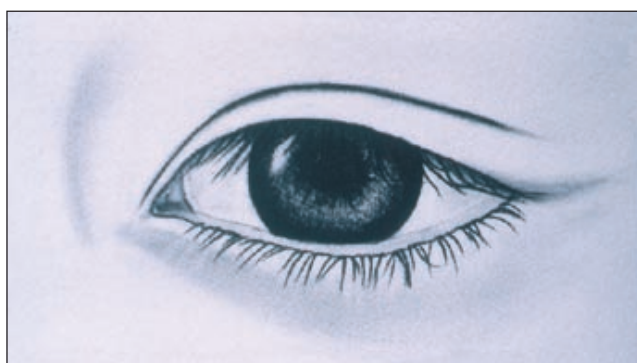


Figure 4. Schematic drawing of a nasally tapered crease configuration. The crease converges to the medial canthus and may either merge into it or remain converging but separated.

The term ‘inner double eyelid’ refers to a medially converging crease — the term ‘nasally-tapered crease’ is less ambiguous (**Figure 4**). The terms inner and outer double eyelids make sense only if one understands the Chinese origin of these terms, as they are translations from Kanji (literally ‘words of the Han race’). Classical literature and Imperial Court correspondence of Japanese and Korean culture from the past 500 years used Kanji. This may be quite confusing for people who are not familiar with the traditional Chinese written language, and it is best to avoid using these terms for medico-legal reasons, since both Chinese and non-Chinese Asians may be using them incorrectly.

The eyelid crease results from the presence of subcutaneous terminal interdigitations of the levator aponeurosis in the pretarsal as well as along the superior tarsal border area. The distal terminations of the levator aponeurosis fibers blend into the intermuscular septal and connective tissue fibers of the pretarsal orbicularis oculi muscle,⁴ resulting in an in-folding when the levator is contracting the upper lid upwards.

Surgical procedures

‘Asian blepharoplasty’ is a term first used in a paper published in 1987 by this author.¹ It describes a distinctive surgical procedure tailored specifically for those Asians without a crease who wish to have one, with reference to details concerning height, shape, and surgical technique to

allow the crease to appear continuous, symmetrical in contour, and to achieve permanency. With an external incision approach, the goal of the surgery is to clear the trapezoidal block of pre-aponeurotic tissue along the superior tarsal border,⁵⁻⁸ which includes skin, orbicularis, and orbital septum as well as minimal pre-aponeurotic fat, in an equi-depth and uniform fashion, to allow for optimal surgical approximation of the terminal fibers of the levator aponeurosis to the under surface of the skin along the superior tarsal border. For a nasally tapered crease, the crease is designed to converge medially, while for a parallel crease, the technique is to stay more level and even along the lid margin.

Another approach is the suture ligation method. Although I do not favor the conjunctival ligation approach, the goal of this technique is to create a surgical adhesion between the soft tissues just above the tarsal plate to the overlying skin, whether the surgical ligature is first inserted from the conjunctival side or the skin side and whether it is ligated with the suture knot buried under the subcutaneous side or the subconjunctival side. This method does not usually involve any excision or removal of soft tissue and does not correct for any anatomic soft tissue redundancy. It works relatively well only for young adults aged up to their early twenties.

For Asians wanting a conservative crease, fat removal is often unnecessary and is to be avoided, as it may lead to a prominent supratarsal sulcus. I have not found it necessary to aggressively remove all the pretarsal fat as I find that it often leads to formation of multiple pseudo-creases in the pretarsal skin area with prominent lymphedema in certain patients.

Often surgeons are persuaded by the patient to create a high crease. Asians generally have a smaller frame than Caucasians, not only in terms of weight and height, but also in the size of their tarsus, eyelid width, and distance from the upper lid margin to the lower boundary of the brow. Since western doctors often consider 9 to 10 mm to be the average upper eyelid crease height, a crease that is considered ‘high’ will be greater than 9 to 10 mm and therefore higher than the superior border of the upper tarsus. This is anatomically inappropriate and aesthetically undesirable, as it tends to lead to lagophthalmos from placement of a ‘skin-levator-skin’ fixation suture or ‘inferior subcutaneous orbicularis-to-levator aponeurosis’ suture. It is almost always undesirable to create a high crease in Asians as the visual image is of a crease bisecting the zone between the eyebrow and the upper eyelid margin.

Some surgeons advocate that in order to reduce fullness in the pretarsal space, aggressive excision of pretarsal fat and some orbicularis is performed to ensure that the pretarsal skin lies flat against the tarsus postoperatively. However, I have found that fullness in the pretarsal area is not always undesirable. When the pretarsal area is abnormally oversized, it is usually a result of a crease that is placed too high (leaving more tissue between the high crease and the lid margin, thereby giving it a full appearance). Aggressive

dissection or excision of pretarsal tissues tends to lead to persistent lymphedema and risks formation of multiple creases in the pretarsal region. It is more effective to create an individually-tailored crease that is based on the height of the tarsus (6.5 to 8.0 mm), and to excise no more than 2 to 3 mm of the pretarsal orbicularis oculi muscle along the inferior cut edge of the skin incision.

Almost all suboptimal results and complications arise from failure to observe the following points. For patients who do not have a crease and desire Asian blepharoplasty, the only important factor for the patient is the crease line that will be created on the upper lids. A line is described by several parameters, and can be described by its length (the horizontal extent or width along the superior tarsal border); the geometric configuration (shape); the relative separation from the eyelash margin (height) and its relationship to the medial and lateral canthi; whether the crease is continuous or broken (continuity); and whether it remains permanent in appearance (permanency). Symmetry between the two lids can occur only if all of the above parameters are accurate, correct, and equally well performed on both sides.

Review

By now, it is clear that Asian eyelid surgery is not as straightforward as it first appears. The surgery demands nothing short of perfection in all of the points raised above. For example, if the shape is not properly chosen, whether as a parallel crease or a nasally-tapered crease, one can end up with a semilunar crease and a ‘westernized’ look, which is not what an Asian necessarily wants. The Asian patient wants to look like his/her Asian friend who is born with a natural, Asian-looking crease. Equally, a medial bifid crease or a crease with an excessive upward lateral flare may result. Asymmetry may occur between the two creases simply because they are different in shape.

If the height is not correct, based on the central tarsal height, an excessively high crease may result (Figure 5). This can

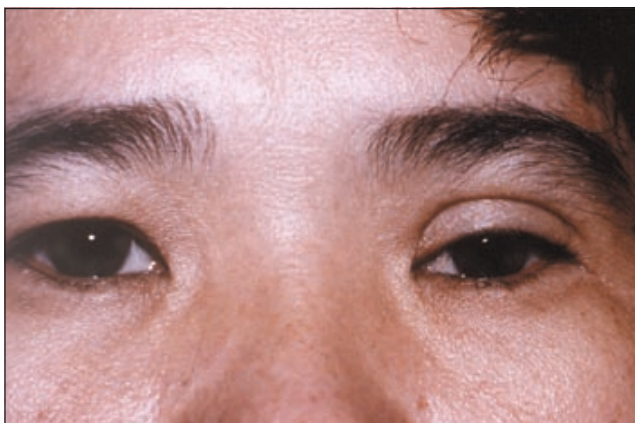

Figure 5. The crease over the left upper eyelid appears high, semilunar, and asymmetric. Contributing factors may include inadvertent high placement of the incision line, excessively high placement of crease forming sutures, excessive dissection in the pre-aponeurotic plane, or excessive fat excision.

occur from incorrect placement of the incision line, poor suture placement, or persistent edema. A low crease may occur although it is rare. Excessive fat removal will lead to a ‘famine’ look with an exaggerated and hollowed supratarsal sulcus (Figure 6), which is very undesirable on an Asian face. Multiple creases (Figure 7) are prone to occur if the incision to the crease line is too high above the superior

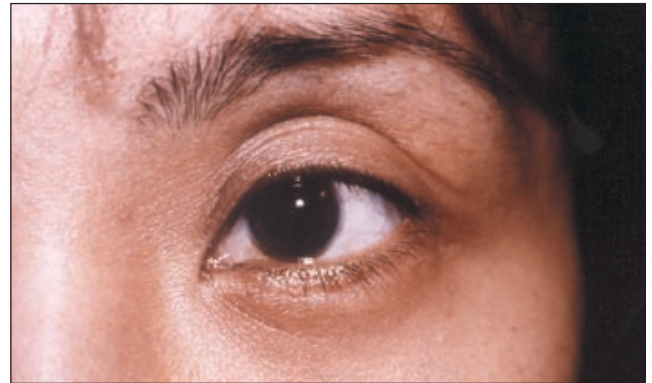


Figure 6. Excessive fat removal has resulted in a prominent supratarsal sulcus. Note the lack of separation from the superior orbital rim of the brow and the visual confusion with a faint rudimentary crease beneath it.

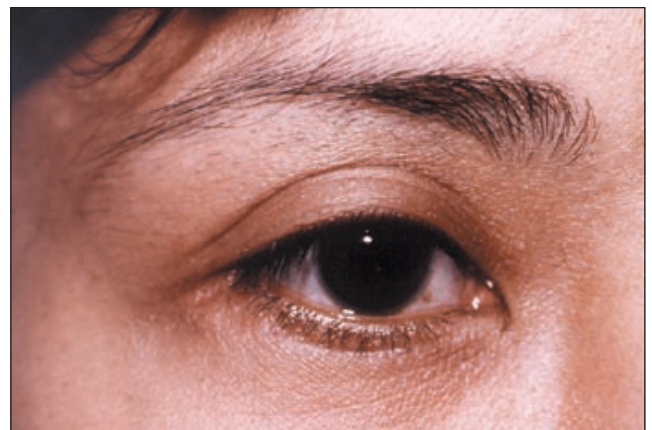


Figure 7. Multiple creases, most likely caused by excessive dissection in the pre-aponeurotic space and the supratarsal sulcus. Similarly, multiple creases can occur in the pretarsal plane from excessive dissection in the pretarsal plane.

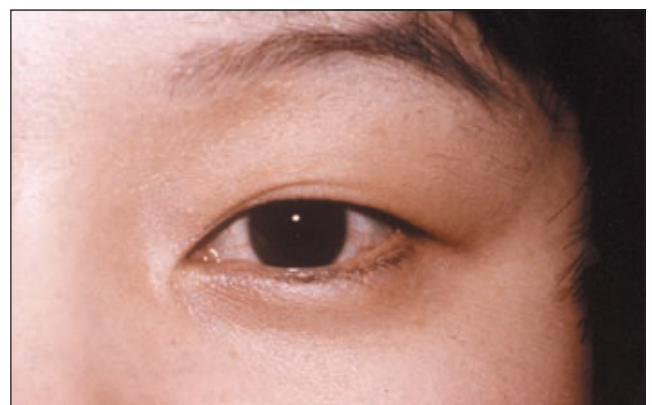


Figure 8. Partial crease formation seen in a young Asian woman following a double eyelid crease procedure utilizing the suture ligation method. The lateral extent of the crease disappeared after four months.

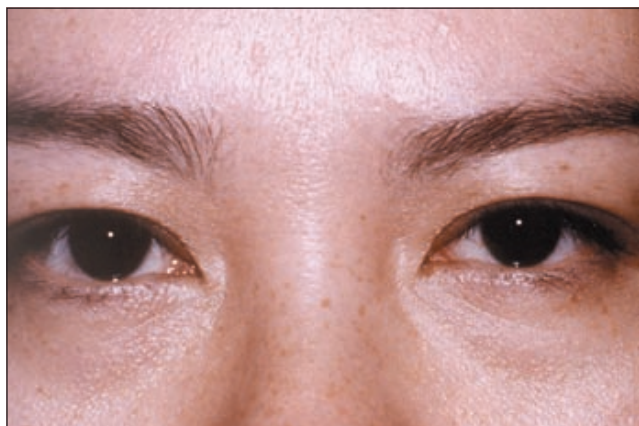


Figure 9. Insufficient excision of the skin using the external incision method for crease formation has resulted in residual hooding of the upper lid. The creases appear shielded even though they were appropriately placed and shaped.

tarsal border or if excessive dissection was performed along the pretarsal plane and within the post-septal pre-aponeurotic space.

Problems with continuity can give rise to a fragmented (discontinuous) crease, a shallow looking crease, or a partially (Figure 8) or completely obliterated crease. An otherwise properly formed crease may look obliterated due to inadequate removal of the skin above it. This results in 'hooding' of the eyelid tissue above the crease, in essence shielding the real crease when the individual is viewed face on (Figure 9).

Permanency problems include late disappearance of the crease (which is seen more with the conjunctival suturing method widely practiced in Japan and China), and downward shifting and progressive shallowing of the crease (Figure 10). The latter arises from inadequate sub-dermal attachment of the distal fibers of the levator aponeurosis at the level of the superior tarsal border. Fading of the medial

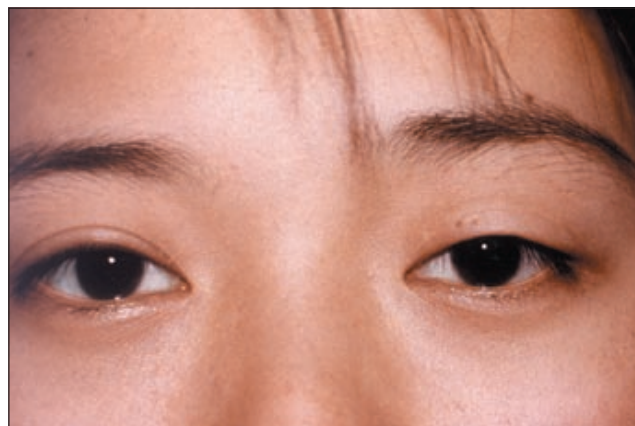

Figure 10. A young woman who underwent a conjunctival suturing procedure for creation of a lid crease. The left upper lid crease disappeared after one year.

one-third of the crease is also a fairly common occurrence and is often due to an inability to adequately fixate the most medial portion of the levator aponeurosis to the skin edges. The result is a crease that runs over the lateral two-thirds of the palpebral fissure.

If the correct length (width), shape, and height, is achieved and kept continuous, permanent, and equal on both sides, then all the identifiable surgical variables have been eliminated and symmetry and optimal results can be achieved, barring unforeseen variables such as bleeding (hypertension, bleeding disorders, and use of herbal medicines or anti-coagulants), propensity for scar formation, variation in skin type, and poor patient compliance.

As a corollary to this discussion, it is important to note that any correction of suboptimal results in Asian eyelid surgery requires accurate identification of the causes, followed by cooperative correction of the parameters involved.

References

1. Chen WP. Asian blepharoplasty — anatomy and technique. *J Ophthalm Plast Reconstr Surg* 1987;3(3):135-140.
2. Chen WP. A comparison of Caucasian and Asian blepharoplasty. *Ophthalmic Pract* 1991;9(5):216-222.
3. Uchida J. A surgical procedure for blepharoptosis vera and for pseudo-blepharoptosis orientalis. *Br J Plast Surg* 1962;15:271-276.
4. Collin JR, Beard C, Wood I. Experimental and clinical data on the insertion of the levator palpebrae superioris muscle. *Am J Ophthalmol* 1978;85:792-801.
5. Chen WPD. *Asian blepharoplasty (a surgical atlas)*. Newton: Butterworth and Heinemann, 1995.
6. Chen WPD. Concept of triangular, rectangular and trapezoidal debulking of eyelid tissues: application in Asian blepharoplasty. *Plast Reconstr Surg* 1996;97(1):212-218.
7. Chen WP. Upper eyelid blepharoplasty in the Asian patient. In Putterman A (ed). *Cosmetic oculo-plastic surgery*. 3rd ed. Philadelphia: WB Saunders, 1998.
8. Chen WPD. Eyelid and eyelid skin diseases. In Lee D, Higginbotham E (eds). *Clinical guide to comprehensive ophthalmology*. New York: Thieme Medical Publishers, Inc., 1998.