

Bilateral pigmentary chorioretinal lesions

Dr Patrick K. W. Wu, FRCS, FHKAM (Ophth)

Department of Ophthalmology, Tung Wah Eastern Hospital, Hong Kong, China.

Question

A 52-year-old Thai woman presented with grittiness over both eyes for several months. Her best corrected visual acuities were 0.1 and 0.6 in the right and left eyes, respectively. At history taking, she was found to have poor vision in one eye for unknown reason since childhood and she had had no previous ophthalmic assessment.

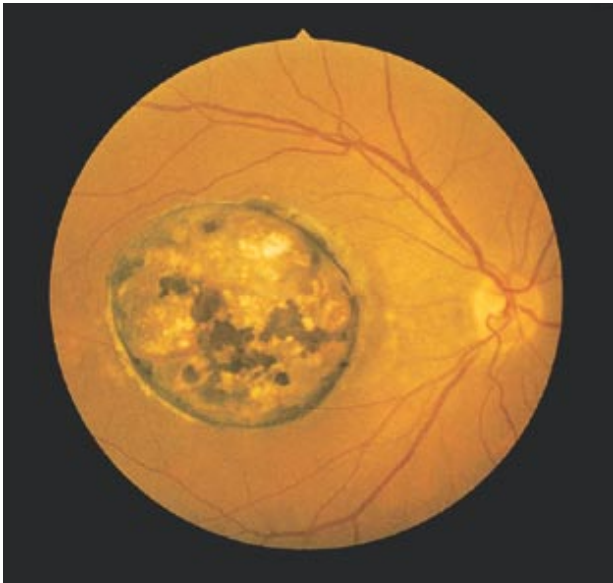


Figure 1. Fundus of right eye.

Her general past health was good and there was no family history of eye disease.

Ocular examination revealed blepharitis and trichiasis on both eyelids. Anterior segment examination was essentially normal. The fundus photos are shown in **Figures 1 and 2**.

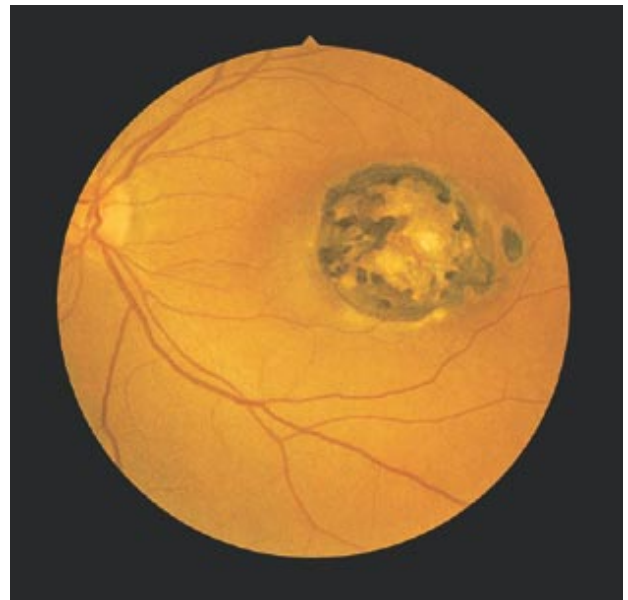


Figure 2. Fundus of left eye.

What is the diagnosis?

(Answer and discussion on page 49)