

# Evaluation of macular holes by optical coherence tomography in Chinese patients

Yong Li, MD, Hong Dai, MD, Zian Shi, MD, Long Li, MD, Ya-Fen Di, MD  
Department of Ophthalmology, Beijing Hospital, Beijing 100730, China.

## Correspondence and reprint requests:

Yong Li, Department of Ophthalmology, Beijing Hospital, No. 1 Dahua Rd. Dongdan, Beijing 100730, China.

## Abstract

**Aim:** To evaluate the diagnostic significance of optical coherence tomography for macular holes.

**Materials and methods:** From October 1999 to February 2000, forty six eyes of 40 patients with clinically diagnosed or suspected macular holes had optical coherence tomography performed via dilated pupils in both eyes. All images were measured and analyzed.

**Results:** The optical coherence tomography technique showed lamellar macular holes in 11 eyes of 9 patients with partial neural epithelium defect. The average remaining retinal thickness of the macular area was 108  $\mu\text{m}$  (standard deviation, 42.5  $\mu\text{m}$ ). Thirty eyes of 27 patients had full-thickness macular holes. The average diameter of the holes was 611  $\mu\text{m}$  (standard deviation, 185.1  $\mu\text{m}$ ). The optical coherence tomography technique showed that the neural epithelium disappeared completely in full-thickness macular holes and the average thickness of the retina around the holes increased to  $388.4 \pm 109.8 \mu\text{m}$  with the presence of non-reflective cavities. The macular holes closed in 5 eyes after vitrectomy and gas tamponade. The normal foveal curve reappeared after surgery. Pseudoholes were present in the remaining 5 eyes of 4 patients.

**Conclusion:** Optical coherence tomography is a non-contact, non-invasive, and high-resolution technique that is helpful in the diagnosis and monitoring of macular holes.

## Introduction

Idiopathic macular hole is a common retinal disease among elderly people. Since the first description of macular holes in 1871,<sup>1</sup> their clinical characterization and theories of their pathogenesis have continued to evolve. Tangential vitreous traction of the premacular vitreous cortex<sup>2</sup> or traction via epiretinal membrane formation<sup>3</sup> are possible causes of macular holes. A study by Gass and Joondeph showed that incorrect interpretation of biomicroscopic findings is common, leading to incorrect diagnosis of macular holes and their staging with important consequences for therapeutic decision making.<sup>4</sup> The lack of definitive criteria for surgical intervention and the variable outcomes may be due to an inability to clearly identify the stages or the actual evolutionary process of macular hole formation.

Optical coherence tomography (OCT) is a new retinal imaging technique that has application for the diagnosis and management of a variety of diseases of the macula and optic nerve. OCT produces cross-sectional images of optical reflectivity from the retina, similar to ultrasound B-scan, but with higher resolution. Measurements of retinal thickness may be obtained directly from the tomogram, either by manually measuring the distance between the inner and outer retinal boundaries or by using computer image processing techniques.<sup>5</sup> OCT is not limited by the ocular aperture, has high sensitivity and reproducibility, and achieves a high axial resolution of approximately 10  $\mu\text{m}$ .<sup>6</sup> The technique is able to demonstrate the abnormal retinal structures of eyes with congenital or senile retinoschisis,<sup>7</sup> macular holes,<sup>8</sup> epiretinal membrane,<sup>9</sup> central serous chorioretinopathy,<sup>10</sup> age-related macular degeneration,<sup>11</sup> and macular edema.<sup>12</sup> The images obtained can be stored, reviewed, and analyzed to measure the actual length of the intraretinal structures.<sup>13</sup> In our cross

*Key words:* Optical coherence tomography, Macular hole

sectional analysis we used OCT to evaluate and monitor a group of patients with macular holes at different stages.

### Materials and methods

From October 1999 to February 2000, forty six eyes of 40 patients were diagnosed with or suspected to have macular hole by the history, visual acuity, direct and indirect funduscopy, slit-lamp biomicroscopy, and fluorescein fundus angiography. OCT images were obtained with an optical coherence tomographic scanner (OCT 2000 version A 4.01, Carl Zeiss-Humphrey Systems, Dublin, USA) via a dilated pupil. Each OCT was centered on the patient's fixation, which was assumed to correspond to the central fovea. In patients with eccentric or imperfect fixation, the

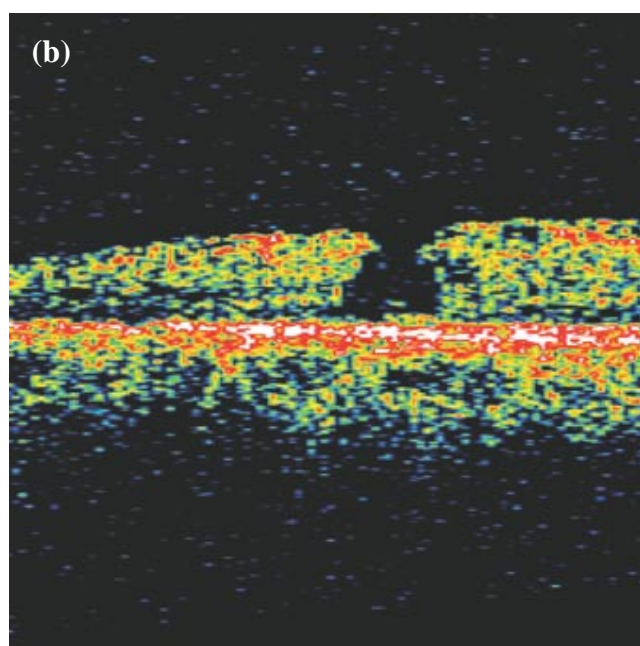
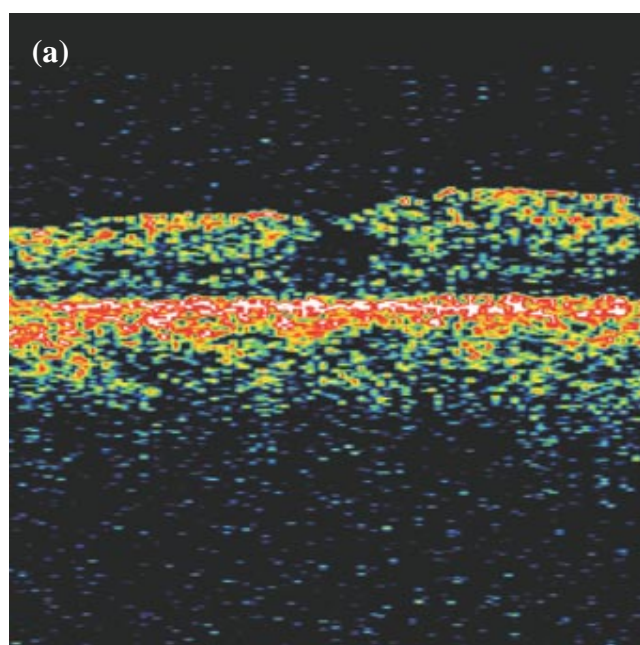


Table 1. Visual acuities of the patients in the study.	
Snellen visual acuities	No. of eyes
< 0.1	14
0.1 to < 0.3	18
0.3 to < 0.5	8
≥ 0.5	6

examiner offset the OCT during data acquisition so that the fovea would be centrally positioned. The linear scan length was 4 mm. Four scans were obtained at 45° angular orientations apart from a radial spoke pattern centered on the fovea. A computer algorithm was used to profile the inner and outer retinal boundaries for each tomogram. Each of the 4 tomograms was smoothed by linear convolution with a center-weighted kernel. An edge-detection kernel was then used to locate the strongest 2 edges in each tomogram that were most likely to correspond to the vitreo-retinal interface and the retinal pigment epithelium. The macular hole diameter was obtained at the innermost edges of the retinal defect. All data and images were stored, measured, and analyzed by the computer.

The decision to undergo the surgery was made by the patients. Due to the difficulty of the operation, patients' traditional reluctance to undergo surgery, and the uncertain prognosis in China (which is now improving), posterior vitrectomy was performed for only 5 eyes.

After posterior vitrectomy, 20% perfluoroethane was injected into the vitreous cavity and the patients were managed in the prone position for 10 to 14 days postoperatively. These patients were followed up for at least for 6 months. OCT was performed 2 to 3 weeks and 3 months postoperatively. Patients who did not have surgery were followed up every 3 months.

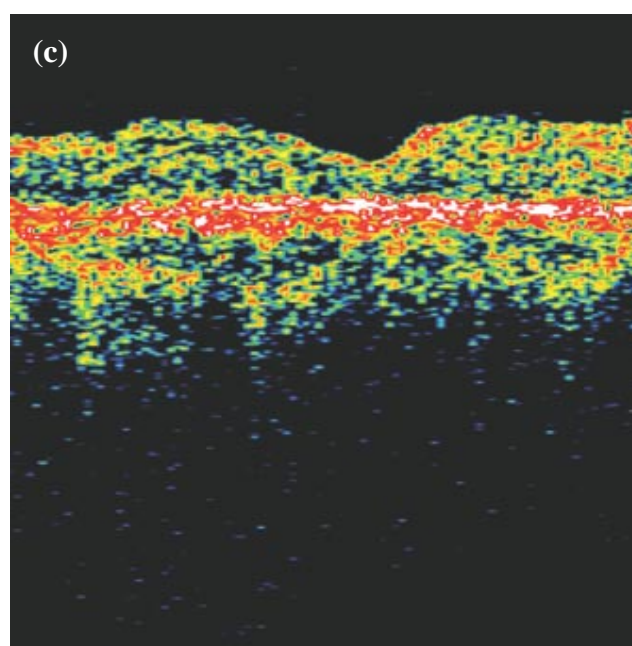


Figure 1. Optical coherence tomography showing (a) a low reflectivity cavity at the fovea; (b) a partial defect of neural epithelium; and (c) a normal curvature of the fovea of a postoperative sealed hole.

## Results

Of the 40 patients in the study, 21 were men and 19 were women. The ages ranged from 48 to 83 years (average,  $65.2 \pm 9.1$  years). The average follow-up period was  $6.0 \pm 1.4$  months. All patients complained of metamorphopsia or decreased vision. There were no other eye diseases present except for 1 patient who had a history of eye trauma. The visual acuities of the patients are shown in **Table 1**.

Eleven eyes of 9 patients had lamellar holes. OCT showed a partial defect of the neural epithelium. The average remaining thickness was  $108 \mu\text{m}$ , (standard deviation [SD],  $42.5 \mu\text{m}$ ). Among these patients, 1 had previous eye trauma with dislocation of the crystalline lens and low intraocular pressure. During follow-up, OCT first showed macular cystoid changes that gradually converted to a lamellar hole. Vitrectomy and gas tamponade were performed for this patient. After operation, the hole was sealed and the normal foveal curvature reappeared in OCT (**Figure 1**). The vision increased from 0.3 to 0.5 and the metamorphopsia disappeared.

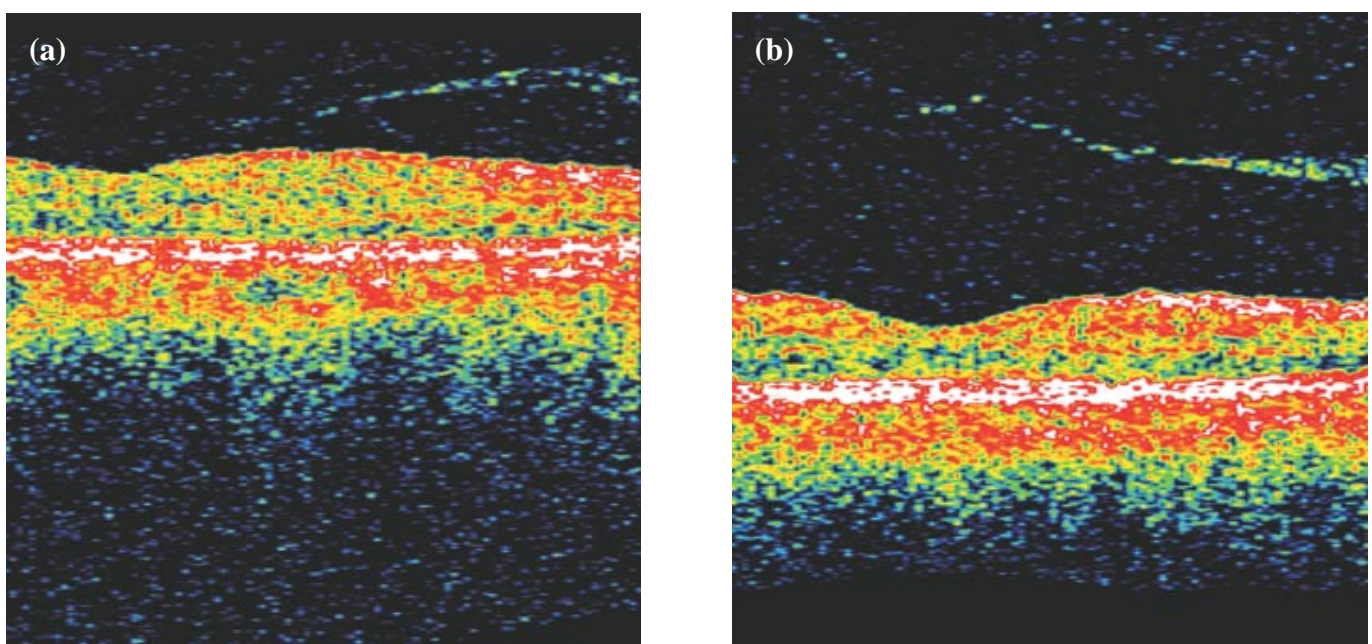
Thirty eyes of 27 patients had true macular holes. According to Gass's classification,<sup>14</sup> the macular holes in this group corresponded to stage II in 6 eyes, stage III in 19 eyes, and stage IV in 5 eyes. OCT showed that the neural epithelium disappeared completely at the fovea with sharp edges. The retina was thickened around the hole with non-reflective intraretinal cavities. The average thickness of the thickened retina was  $388.4 \mu\text{m}$  (SD,  $109.8 \mu\text{m}$ ). The average hole diameter was  $611 \mu\text{m}$  (SD,  $185.1 \mu\text{m}$ ). Ten of these eyes had caps above the holes. Four eyes underwent vitrectomy and all had pre-existing posterior vitreous detachment (PVD). After surgery, the holes were sealed and the retina reattached, and the normal fovea curve reappeared. Only 1 patient had

2 lines increase in visual acuity, while the others had no change in vision. During follow-up, 2 eyes had postoperative reopening of the macular hole. Five eyes of 4 patients had pseudoholes with vitreous traction or epiretinal membrane in the macular area. The retinal tissues were intact in these eyes. All 4 patients had visual acuities better than 0.5. Four eyes later advanced to full-thickness macular holes and one eye had PVD without macular hole formation (**Figure 2**).

Of the 40 patients, 19 eyes had epiretinal membrane shown on OCT. Ten of these eyes had full-thickness holes, 5 had lamellar holes, and 4 had pseudoholes. Intraretinal cavities were seen in 30 full-thickness holes, 5 lamellar holes, and 4 pseudoholes.

## Discussion

The suggestion that macular holes originate as intraretinal cysts has been proposed.<sup>15</sup> The process of cyst formation may be due to tangential traction exerted onto the retinal surface, or may be secondary to other factors.<sup>10</sup> Histopathologic studies have shown that epiretinal membranes and cystoid edema are common in full-thickness macular holes. A large histopathologic study of macular cysts and holes by Frangieh et al concluded that cystoid degeneration with cyst coalescence and subsequent hole formation was the most common pathological sequence.<sup>15</sup> This study showed that cystoid degeneration was present in the outer plexiform layer and inner nuclear layer in most eyes with non-traumatic macular holes, as well as in some contralateral eyes of these patients.<sup>15</sup> All non-traumatic lamellar holes had the appearance of a ruptured, large, central, coalesced cyst, resulting in a flask-shaped partial-thickness hole. These researchers found that a fibroglial preretinal membrane was present in the majority of patients with macular holes as well as in the



**Figure 2.** Optical coherence tomography showing (a) a high reflectivity band partially separated from the retina; and (b) a complete separation of high reflectivity band.

majority of those with macular cysts. Nineteen eyes in our study had epiretinal membranes above the holes, 4 of which had pseudoholes and developed true macular holes during follow up. Ten of the 30 eyes with true macular holes had caps above the holes.

In 1995, Gass reappraised a new biomicroscopic classification of stages of development of a macular hole based on a theory of tangential vitreous traction on the macula.<sup>14</sup> In this classification, the initial appearance of an impending hole was caused by posterior foveolar detachment. The operculum over the macula was due to condensation of the vitreous cortex over the fovea and did not contain full thickness foveolar neural tissue. Full thickness macular holes develop as a result of centrifugal displacement of photoreceptors from a central dehiscence of the umbo. This may explain the surprisingly good visual recovery after macular hole surgery. In our group there were 6 eyes with stage II holes, 19 eyes with stage III, and 5 eyes with stage IV. Lamellar holes were detected in 11 eyes and pseudoholes in 5.

Optical sections obtained with OCT have shown that macular holes begin to develop with intraretinal cystic cavities and a break in the internal limiting membrane

over the center of the cavity.<sup>8</sup> Gaudric et al also showed an intraretinal split in the inner part of the foveola and definite adherence of the posterior hyaloid to the foveal center in early macular holes with OCT.<sup>16</sup> Perihole intraretinal cavities were identified in most of our patients, including 31 with full-thickness holes, 5 with lamellar holes, and 4 with pseudoholes.

Vitrectomy with gas tamponade is often performed to treat the rim of localized retinal detachment that surrounds a macular hole. Five of our patients underwent vitrectomy. After surgery, all the holes sealed up and the normal foveal curvature reappeared, although the holes reopened on follow-up for 2 patients.

## Conclusion

We found that OCT was a useful technique for quantitative measurement of retinal thickness and diameter of the holes in patients with macular holes. The topographic mapping protocol provides geographic information of macular thickness, which is precise and objective. This also allows differentiation of different types of holes and observation of the development of early stage holes.

## References

1. Noyes HD. Detachment of the retina, with laceration of the macula lutea. *Trans Am Ophthalmol Soc* 1871;1:128-129.
2. Gass JD. Idiopathic senile macular hole. Its early stages and pathogenesis. *Arch Ophthalmol* 1988;106:629-639.
3. Akiba J, Ishiko S, Hikichi T, Ogasawara H, Yanagiya N, Yoshida A. Imaging of epiretinal membranes in macular holes by scanning laser ophthalmoscopy. *Am J Ophthalmol* 1996;121:177-180.
4. Gass JD, Joondeph BC. Observations concerning patients with suspected impending macular holes. *Am J Ophthalmol* 1990;109:638-646.
5. Izatt JA, Hee MR, Swanson EA, et al. Micrometer-scale resolution imaging of the anterior eye in vivo with optical coherence tomography. *Arch Ophthalmol* 1994;112:1584-1589.
6. Pieroth L, Schuman JS, Hertzmark E, et al. Evaluation of focal defects of the nerve fiber layer using optical coherence tomography. *Ophthalmology* 1999;106:570-579.
7. Azzolini C, Pierro L, Codenotti M, Brancato R. OCT images and surgery of juvenile macular retinoschisis. *Eur J Ophthalmol* 1997;7:196-200.
8. Hee MR, Puliafito CA, Wong C, et al. Optical coherence tomography of macular holes. *Ophthalmology* 1995;102:748-756.
9. Wilkins JR, Puliafito CA, Hee MR, et al. Characterization of epiretinal membranes using optical coherence tomography. *Ophthalmology* 1996;103:2142-2151.
10. Hee MR, Puliafito CA, Wong C, et al. Optical coherence tomography of central serous chorioretinopathy. *Am J Ophthalmol* 1995;120:65-74.
11. Hee MR, Bauman CR, Puliafito CA, et al. Optical coherence tomography of age-related macular degeneration and choroidal neovascularization. *Ophthalmology* 1996;103:1260-1270.
12. Hee MR, Puliafito CA, Wong C, et al. Quantitative assessment of macular edema with optical coherence tomography. *Arch Ophthalmol* 1995;113:1013-1029.
13. Hiraoka H, Iijima H, Gohdo T, Tsukahara S. Optical coherence tomography of cystoid macular edema associated with retinitis pigmentosa. *Am J Ophthalmol* 1999;128:185-191.
14. Gass JD. Reappraisal of biomicroscopic classification of stages of development of a macular hole. *Am J Ophthalmol* 1999;119:752-759.
15. Frangieh GT, Green WR, Engel HM. A histopathologic study of macular cysts and holes. *Retina* 1981;1:311-336.
16. Gaudric A, Haouchine B, Massin P. Macular hole formation: new data provided by optical coherence tomography. *Arch Ophthalmol*. 1999;117:744-751.