

Orbscan and ultrasound pachymetry in patients with ocular hypertension and normal tension glaucoma

Man-Kit Yiu, AFCOphthHK, MRCS (Ed), Chi-Cheong Wong, FRCS (Edin), FHKAM (Ophth),
Siu-Ping Hui, FRCOphth (UK), FRCS (Ed), FHKAM (Ophth)

Tung Wah Eastern Hospital Eye Centre, 19 Eastern Hospital Road, Causeway Bay, Hong Kong, China.

Correspondence and reprint requests:

Man-Kit Yiu, Tung Wah Eastern Hospital Eye Centre, 19 Eastern Hospital Road, Causeway Bay, Hong Kong, China.

Abstract

Aim: To compare central corneal thickness measurements using an ultrasound pachymeter and an Orbscan.

Patients and methods: Normal subjects and patients with ocular hypertension, and with normal tension glaucoma were recruited at the Tung Wah Eastern Hospital Eye Centre, Hong Kong. Central corneal thickness was measured using the ultrasound pachymeter and the Orbscan for one selected eye per patient and the results compared between groups.

Results: Mean central corneal thickness for normal subjects, patients with ocular hypertension, and patients with normal tension glaucoma were $550.1 \pm 21.4 \mu\text{m}$, $598.5 \pm 27.2 \mu\text{m}$, and $525.8 \pm 24.9 \mu\text{m}$, respectively, when measured by ultrasound. Using the Orbscan, mean central corneal thickness was $561.9 \pm 26.0 \mu\text{m}$ for normal subjects, $590.2 \pm 26.4 \mu\text{m}$ for those with ocular hypertension, and $528.8 \pm 28.7 \mu\text{m}$ for those with normal tension glaucoma. Pearson's correlation coefficients between ultrasound and Orbscan measurements were 0.82 ($p < 0.001$), 0.87 ($p < 0.001$), and 0.83 ($p < 0.001$) for normal subjects, those with ocular hypertension, and normal tension glaucoma, respectively.

Conclusions: Central corneal thickness is increased in ocular hypertension but decreased in normal tension glaucoma. Ultrasound and Orbscan measurements of central corneal thickness were highly correlated in this study.

Key words: Cornea, Glaucoma, Ocular hypertension, Ultrasonography

Introduction

Intraocular pressure (IOP) measurement is used in the diagnosis and management of glaucoma. The Goldmann applanation tonometer is the gold standard for IOP measurement but its accuracy is affected by corneal thickness.^{1,2} A thick cornea leads to IOP over estimation, whereas a thin cornea results in under estimation. The arbitrary cutoff point at 21 mm Hg leads to a considerable number of cases in the gray area in which it is difficult to reach a diagnosis. It has been suggested that measurement of corneal thickness is an important step in correlating IOP to clinical findings in glaucoma patients.³

Recent studies have shown a tendency towards greater central corneal thickness (CCT) readings in ocular hypertension (OHT),^{4,6} but lower CCT readings in normal tension glaucoma (NTG).⁷⁻¹⁰ Most of these observations were made using ultrasound pachymeters. Although ultrasound pachymetry is an accurate and reliable measurement tool, it has the disadvantages of requiring corneal anesthesia and probe contact with the cornea. The variable location of probe placement on the corneal surface is an important source of measurement error. There has been increasing interest recently in corneal pachymetry using non-contact methods, including the use of the Orbscan and optical coherence tomography (OCT). The efficacy of corneal pachymetry using OCT in glaucoma patients has been evaluated in several studies.^{11,12} Using OCT to measure CCT is very technically

demanding and less user-friendly than use of the Orbscan. In this study, Orbscan and ultrasound pachymetry CCT readings were compared in patients with OHT and NTG.

Patients and methods

Subjects comprised 3 groups — normal subjects (n=17), patients with OHT (n=16), and patients with NTG (n=13). Ocular hypertension was defined as an IOP measurement >21 mm Hg on at least 2 visits with no treatment for IOP control, an open drainage angle, and absence of features of glaucomatous optic disc cupping and visual field defect typical of glaucoma. Patients with a diagnosis of NTG had optic disc cupping, a visual field defect, an open drainage angle, and IOP measurements consistently <21 mm Hg in the absence of antiglaucoma treatment. The normal group included subjects with an IOP <21 mm Hg and no evidence of glaucoma. Patients with prior intraocular surgery, corneal scars, recent contact lens wear, diabetic retinopathy, steroid usage, or a history of severe blood loss were excluded.

Only one eye per patient was selected for study. For a subject with bilateral OHT, the eye that showed consistently higher IOP readings was chosen. For a patient with NTG, the eye that showed more marked visual field impairment was selected. Random numbers were used to decide which eye to use for analysis. The dominant eye was selected for normal subjects and in situations in which the clinical findings were comparable in both eyes.

Central corneal thickness was measured using the ultrasound pachymeter (DGH-1000, DGH Technology, Exton, USA) and the Orbscan (Orbtek, Inc, Salt Lake City, USA). Eight consecutive ultrasound pachymetry readings were made and the average was taken as the ultrasound CCT measurement. A single Orbscan image was captured and the average thickness in the central 0.5 mm zone of the cornea was taken as the Orbscan CCT reading. The same examiner performed all CCT measurements.

The mean CCT measurements for the different groups were compared using the independent samples t-test. Statistical

analysis was performed using the Statistical Packages for the Social Sciences 10.0 for Windows (SPSS Inc., Chicago, USA).

Results

The mean CCT measurements from Orbscan and ultrasound pachymetry assessment were $561.9 \pm 26.0 \mu\text{m}$ and $550.0 \pm 21.4 \mu\text{m}$, respectively, in normal subjects. This compared to $590.2 \pm 26.4 \mu\text{m}$ for Orbscan measurement and $598.5 \pm 27.2 \mu\text{m}$ for ultrasound measurement in patients with OHT. In patients with NTG, the mean CCT was $528.8 \pm 28.7 \mu\text{m}$ when measured by Orbscan, and $525.8 \pm 24.9 \mu\text{m}$ when measured by ultrasound (**Table 1**).

Orbscan measurement showed that patients with OHT had a higher mean CCT (+28.3 μm , 95% confidence interval [C.I.] +9.7 to +46.9 μm , $p = 0.004$) whereas NTG subjects had a lower mean CCT (-36.1 μm , 95% C.I. -16.8 to -55.3 μm , $p = 0.001$) than normal subjects. Ultrasound pachymeter readings yielded similar results. The mean CCT was higher in patients with OHT (+48.4 μm , 95% C.I. +31.1 to +65.8 μm , $p < 0.001$) and lower in NTG subjects (-21.3 μm , 95% C.I. -2.5 to -40.0 μm , $p = 0.028$).

When Orbscan and ultrasound readings were compared, the Pearson correlation coefficients were 0.82 ($p < 0.001$) in normal subjects, 0.87 ($p < 0.001$) in patients with OHT, and 0.83 ($p < 0.001$) in patients with NTG (**Figures 1 to 3**).

Discussion

Goldmann applanation tonometry is based on the Imbert-Fick principle that the pressure of a fluid-filled sphere is equal to the pressure required to flatten its surface. The measurement of IOP can be influenced by corneal thickness because the cornea resists the flattening induced by applanation pressure. CCT is assumed to be 500 μm during calibration of the Goldmann tonometer.¹

One of the potential clinical applications of corneal pachymetry is the adjustment of IOP measured by applanation

Table 1. Summary of patient characteristics, central corneal thickness measurements, and statistical results.

	Normal subjects (n=17)	Patient with ocular hypertension (n=16)	Patient with normal tension glaucoma (n=13)
Mean age (range) [years]	64.4 \pm 9.2 (42 - 76)	57.7 \pm 15.9 (29 - 81)	65.2 \pm 11.4 (42 - 77)
Male:female ratio	10:7	7:9	5:8
Mean central corneal thickness by Orbscan (SD)[μm]	561.9 \pm 26.0 (515.6 - 604.6)	590.2 \pm 26.4 (565.0 - 653.0)	528.8 \pm 28.7 (475.1 - 561.0)
Mean central corneal thickness by ultrasound pachymetry (SD)[μm]	550.1 \pm 21.4 (515.4 - 579.3)	598.5 \pm 27.2 (555.0 - 651.0)	525.8 \pm 24.9 (476.5 - 562.0)
Comparison with mean central corneal thickness measurement in normal subjects: Orbscan (95% CI)[μm]	—	+28.3 (+9.7 - +46.9) $p = 0.004$	-36.1 (-16.8 - -55.3) $p = 0.001$
Comparison with mean central corneal thickness measurement in normal subjects: ultrasound (95% CI)[μm]	—	+48.4 (+31.1 to +65.8) $p < 0.001$	-21.3 (-2.5 to -40.0) $p = 0.028$
Correlation between Orbscan and ultrasound pachymetry central corneal thickness measurements	0.82 $p < 0.001$	0.87 $p < 0.001$	0.83 $p < 0.001$

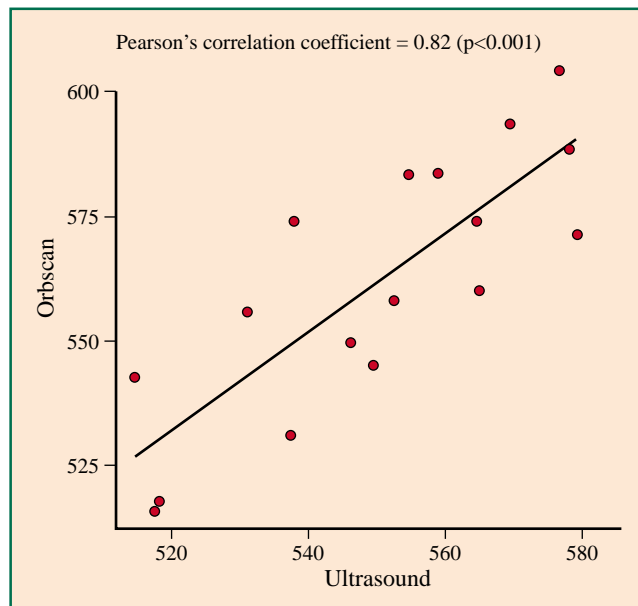


Figure 1. Orbscan and ultrasound central corneal thickness readings in healthy controls.

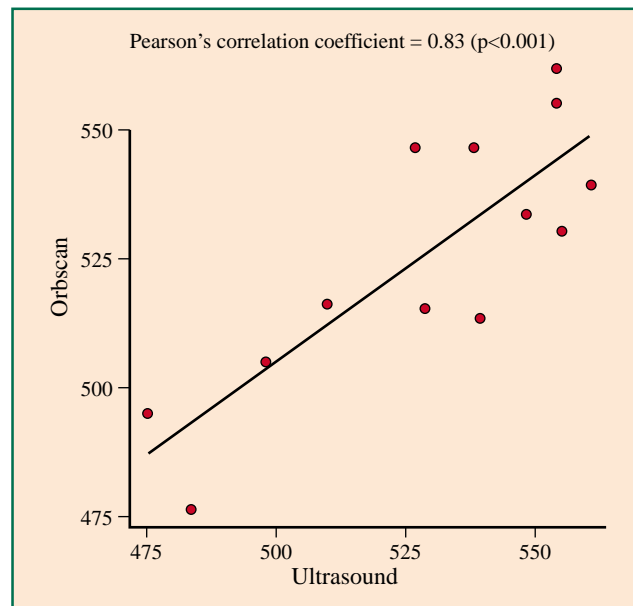


Figure 3. Orbscan and ultrasound central corneal thickness readings in patients with normal tension glaucoma.

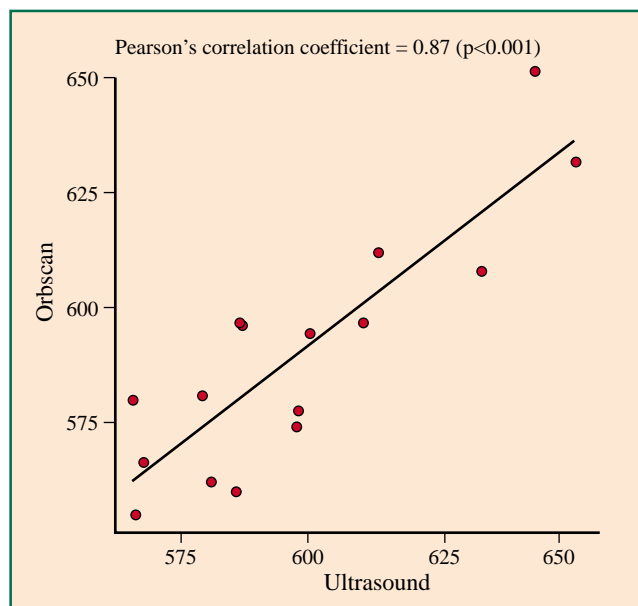


Figure 2. Orbscan and ultrasound central corneal thickness readings in patients with ocular hypertension.

tonometry according to corneal thickness. However, there is controversy concerning the values used to correct IOP for changes in corneal thickness. Reported figures vary greatly, from 5 mm Hg/70 μm^1 to just 2 mm Hg/100 μm^2 . Ehlers et al¹ suggested that if the true IOP was 20 mm Hg, there would be an underestimation of 5.2 mm Hg for a CCT of 450 μm and an overestimation of 4.7 mm Hg for a CCT of 590 μm . According to Whitacre et al,² however, the change in IOP was only 1.3 mm Hg per 70 μm change in CCT. Emara et al¹⁴ reported correlations between IOP and CCT in pre- and post-laser in situ keratomileusis patients in the order of 1 mm Hg per 31.3 to 37.8 μm change in CCT.

For a thick cornea that exceeds the normal value by 50 μm , a 1 to 4 mm Hg correction in IOP may be justified. This

adjustment may be sufficient to decrease the IOP to the cutoff point of 21 mm Hg in some OHT subjects. Therefore, measurement of CCT may help clinicians classify subjects into normal and OHT groups. Many OHT patients appear to have elevated IOP because their corneas are thick and these patients may not be at higher risk of developing glaucoma.

In contrast, CCT is generally lower in NTG subjects so that applanation tonometry tends to give an underestimation of the true IOP in this patient group. For an apparent IOP of 20 mm Hg, the true IOP may be as high as 25 mm Hg if the CCT is 450 μm . The apparently low IOP may give false reassurance and mask progressive glaucomatous damage in NTG patients.

It is known that corneal thickness decreases with age at an estimated rate of 6.3 μm per decade.¹³ Although there were differences in age between different groups of subjects in this study, we believe these differences were not clinically significant given the relatively small magnitude of CCT change in relation to age reported in the literature.

In this study, Orbscan and ultrasound pachymetry readings were highly correlated in the 3 groups of subjects. Orbscan has advantages over ultrasound pachymetry in that corneal anesthesia is not required. The non-contact nature of Orbscan eliminates risks such as corneal abrasion, and disease transmission via probe contact with the cornea. Orbscan images enable analysis to be made over a large area, potentially covering the entire corneal surface. Other useful data, such as corneal curvature, and anterior and posterior elevation maps can be obtained and digitally stored. Compared with pachymetry using optical coherence tomography, Orbscan pachymetry is more user-friendly and technically less demanding.

In summary, this study has defined CCT characteristics in patients with OHT and NTG, using ultrasound and

Table 2. Comparison of central corneal thickness measurements from this study with those reported in the literature.

Studies	Measurement method	Normal subjects	Patients with ocular hypertension	Patients with normal tension glaucoma
Current study	Orbscan	561.9 ± 26.0 μm (n = 17)	590.2 ± 26.4 μm (n = 16)	528.8 ± 28.7 μm (n = 13)
Copt et al ¹⁵	Ultrasound	552 ± 35 μm (n = 18)	583 ± 34 μm (n = 44)	521 ± 31 μm (n = 22)
Argus ¹⁶	Ultrasound	567 ± 36 μm (n = 29)	610 ± 33 μm (n = 36)	—
Herman et al ¹⁷	Optical pachymeter	563 ± 27 μm (n = 55)	594 ± 37 μm (n = 55)	—
Bechmann et al ¹¹	Optical coherence tomography	530 ± 32 μm (n = 36)	593 ± 35 μm (n = 22)	482 ± 28 μm (n = 42)
Ventura et al ¹²	Optical coherence tomography	524 ± 25 μm (n = 21)	569 ± 29 μm (n = 12)	518 ± 0.5 μm (n = 34)

Figures are presented as mean±standard deviation

Orbscan pachymetry. CCT is increased in OHT but decreased in NTG compared with normal eyes. This is in agreement with results from other studies (Table 2).^{11,12,15-17} A positive correlation exists between CCT and IOP and this has led to discussion of whether CCT measurement should be an important step in managing glaucoma. The current issue is

whether there could be better alternatives to ultrasound pachymetry for measuring CCT. Orbscan and ultrasound measurements were highly correlated in this study. Given the many advantages of Orbscan over ultrasound pachymetry, this suggests a potential clinical application of Orbscan in the management of glaucoma.

References

- Ehlers N, Bramsen T, Sperling S. Applanation tonometry and central corneal thickness. *Acta Ophthalmol* 1975;53:34-43.
- Whitacre MM, Stein RA, Hassanein K. The effect of corneal thickness on applanation tonometry. *Am J Ophthalmol* 1993;115:592-596.
- Shah S, Chatterjee A, Mathai M, et al. Relationship between corneal thickness and measured intraocular pressure in a general ophthalmology clinic. *Ophthalmology* 1997;106:2154-2160.
- Argus WA. Ocular hypertension and central corneal thickness. *Ophthalmology* 1995;102:1810-1812.
- Herndon LW, Choudhri SA, Cox TM, Damji KF, Shields MB, Allingham RR. Central corneal thickness in normal, glaucomatous, and ocular hypertensive eyes. *Arch Ophthalmol* 1997;115:1137-1141.
- Herman DC, Hodge DO and Bourne WM. Increased corneal thickness in patients with ocular hypertension. *Arch Ophthalmol* 2001;119:334-336.
- Copt RP, Thomas R, Mermoud A. Corneal thickness in ocular hypertension, primary open-angle glaucoma, and normal tension glaucoma. *Arch Ophthalmol* 1999;117:4-16.
- Brusini P, Miani F, Tosoni C. Corneal thickness in glaucoma: an important parameter? *Acta Ophthalmol Scand Suppl* 2000;78:41-42.
- Wu LL, Suzuki Y, Ideta R, Araie M. Central corneal thickness of normal tension glaucoma patients in Japan. *Jpn J Ophthalmol* 1999;44:643-647.
- Morad Y, Sharon E, Hefetz L, Nemet P. Corneal thickness and curvature in normal-tension glaucoma. *Am J Ophthalmol* 1997;125:164-168.
- Bechmann M, Thiel MJ, Roesen B, Ullrich S, Ulbig MW, Ludwig K. Central corneal thickness determined with optical coherence tomography in various types of glaucoma. *Br J Ophthalmol* 2000;84:1233-1239.
- Ventura ACS, Bohnke M, Mojon DS. Central corneal thickness measurements in patients with normal tension glaucoma, primary open angle glaucoma, pseudoexfoliation glaucoma, or ocular hypertension. *Br J Ophthalmol* 2001;85:792-795.
- Brandt JD, Beiser JA, Kass MA, Gordon MO. Central corneal thickness in the Ocular Hypertension Treatment Study (OHTS). *Ophthalmology* 2001;108:1779-1788.
- Emara B, Probst LE, Tingey DP, Kennedy DW, Willms LJ, Machat J. Correlation of intraocular pressure and central corneal thickness in normal myopic eyes and after laser in situ keratomileusis. *J Cataract Refract Surg* 1998;24:1320-1325.
- Copt R, Thomas R, Mermoud A. Corneal thickness in ocular hypertension, primary open-angle glaucoma, and normal tension glaucoma. *Arch Ophthalmol* 1999;117:14-16.
- Argus WA. Ocular hypertension and central corneal thickness. *Ophthalmology* 1995;102:1810-1812.
- Herman DC, Hodge DO, Bourne WM. Increased corneal thickness in patients with ocular hypertension. *Arch Ophthalmol* 2001;119:334-336.